

# ULTRASONIDO ABDOMINAL

DR.EDUARDO SAMPSON Z.  
VIDA CARE DIAGNOSTICO

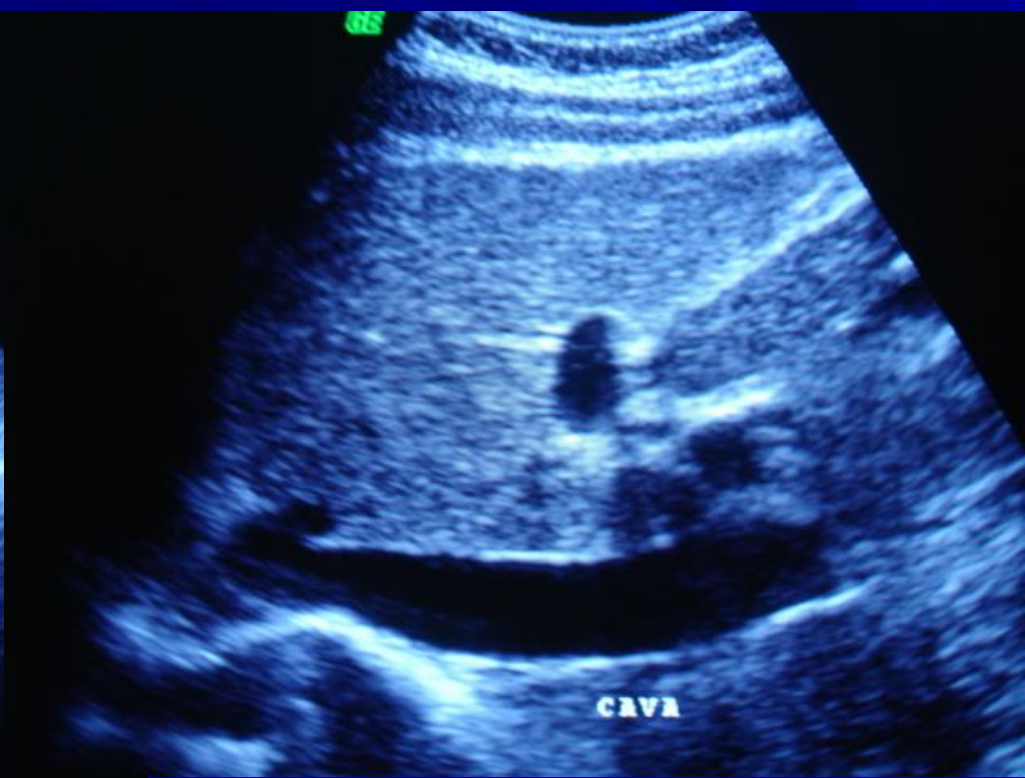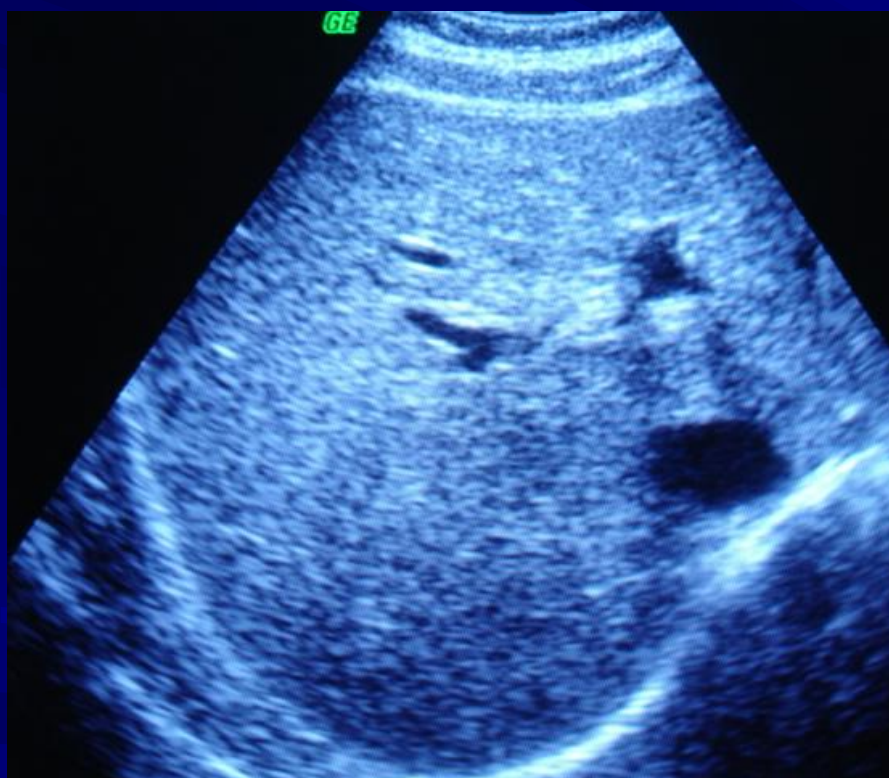
# US DE ABDOMEN

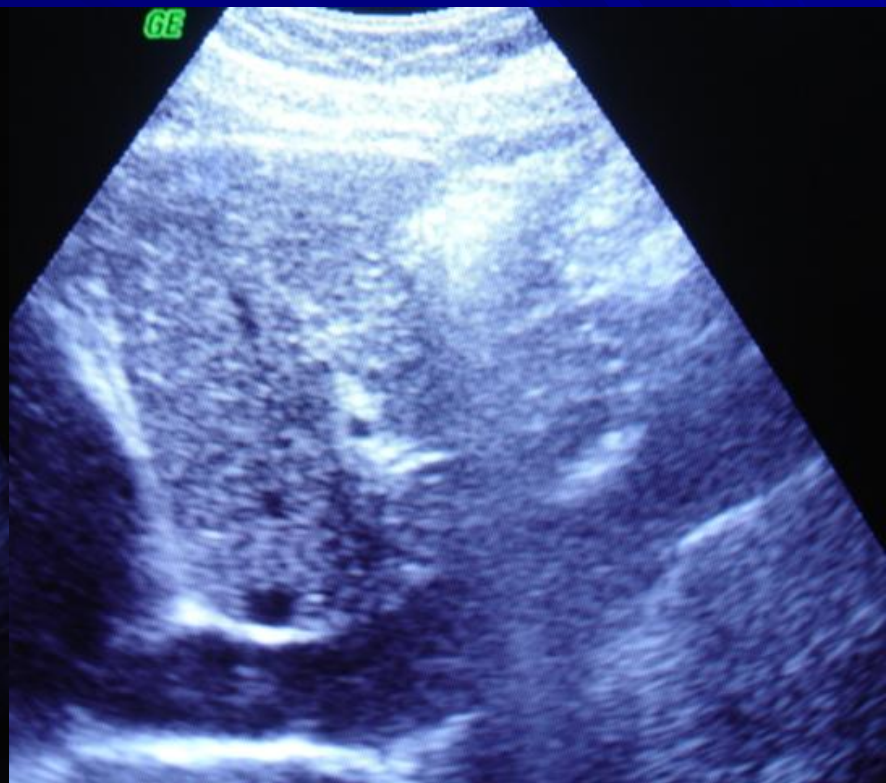
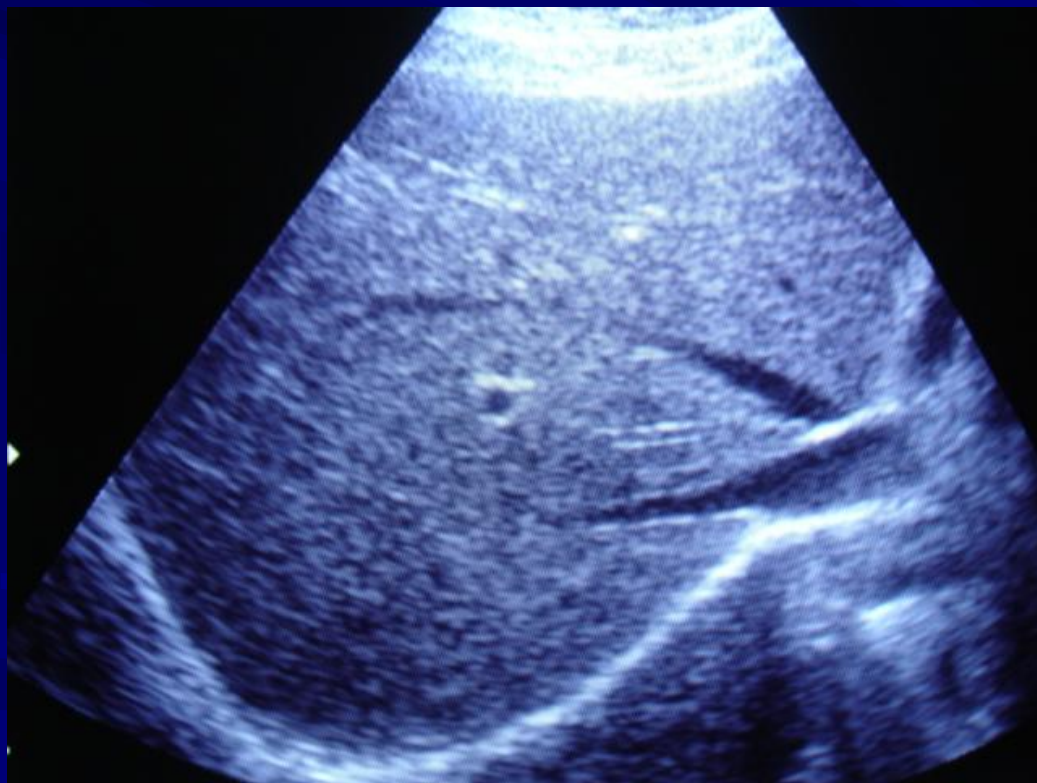
## \* PREPARACION

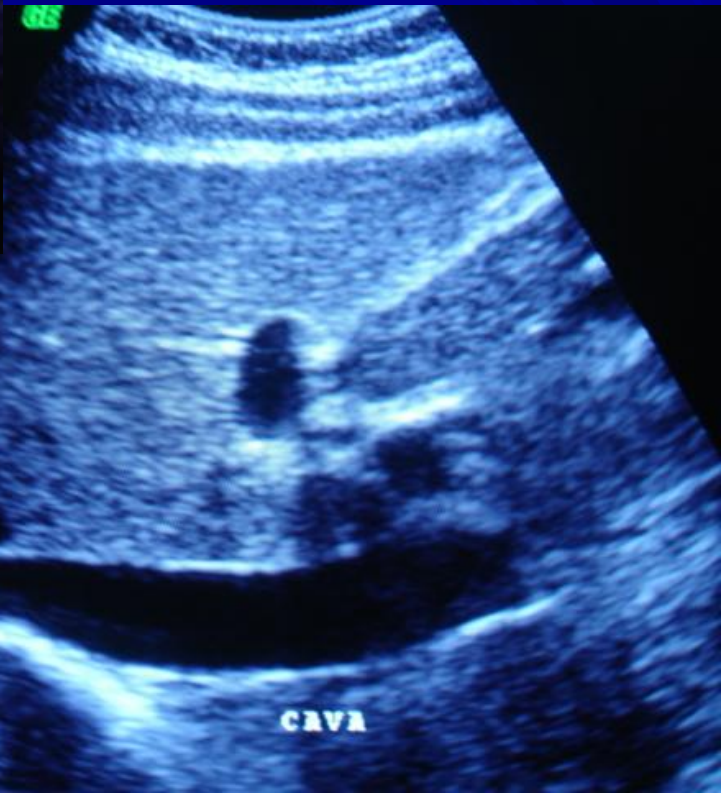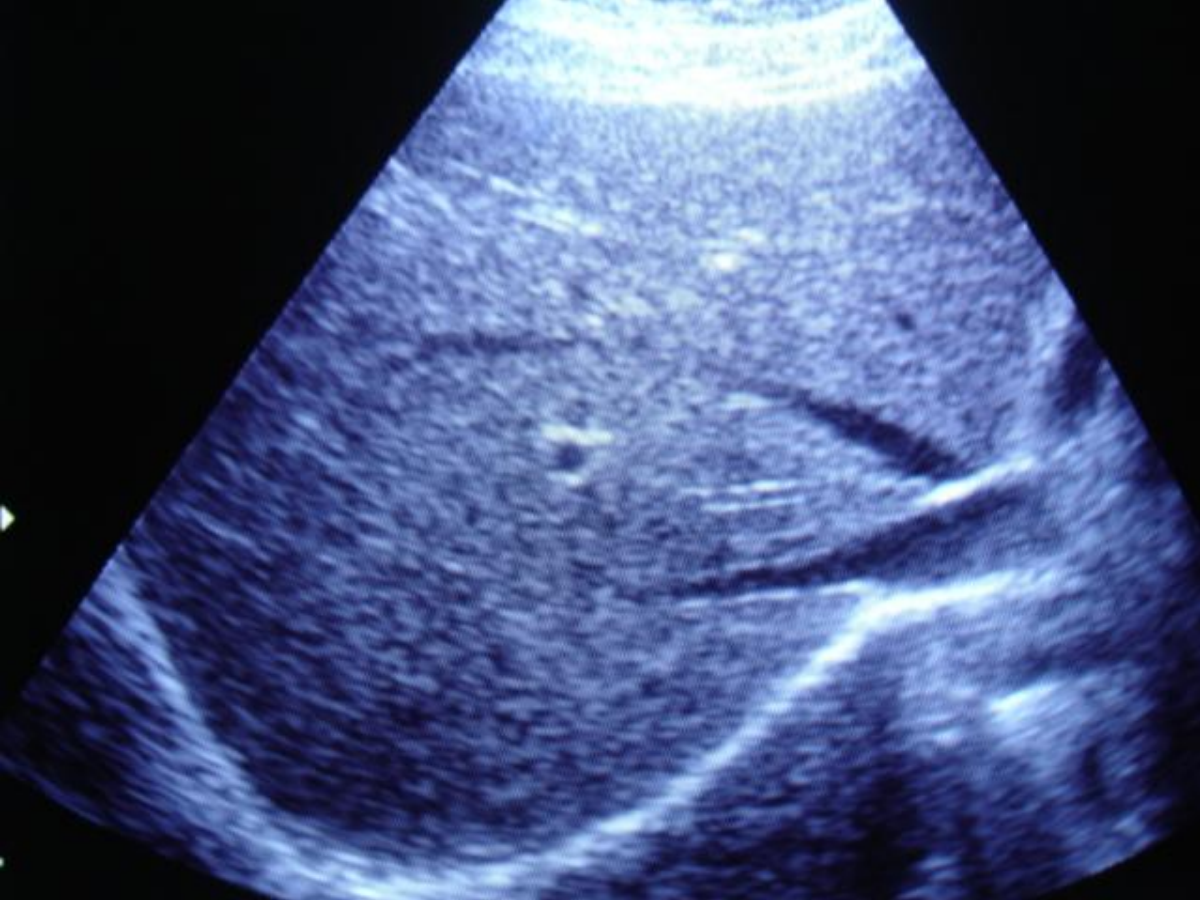AYUNO DE 6 HRS.

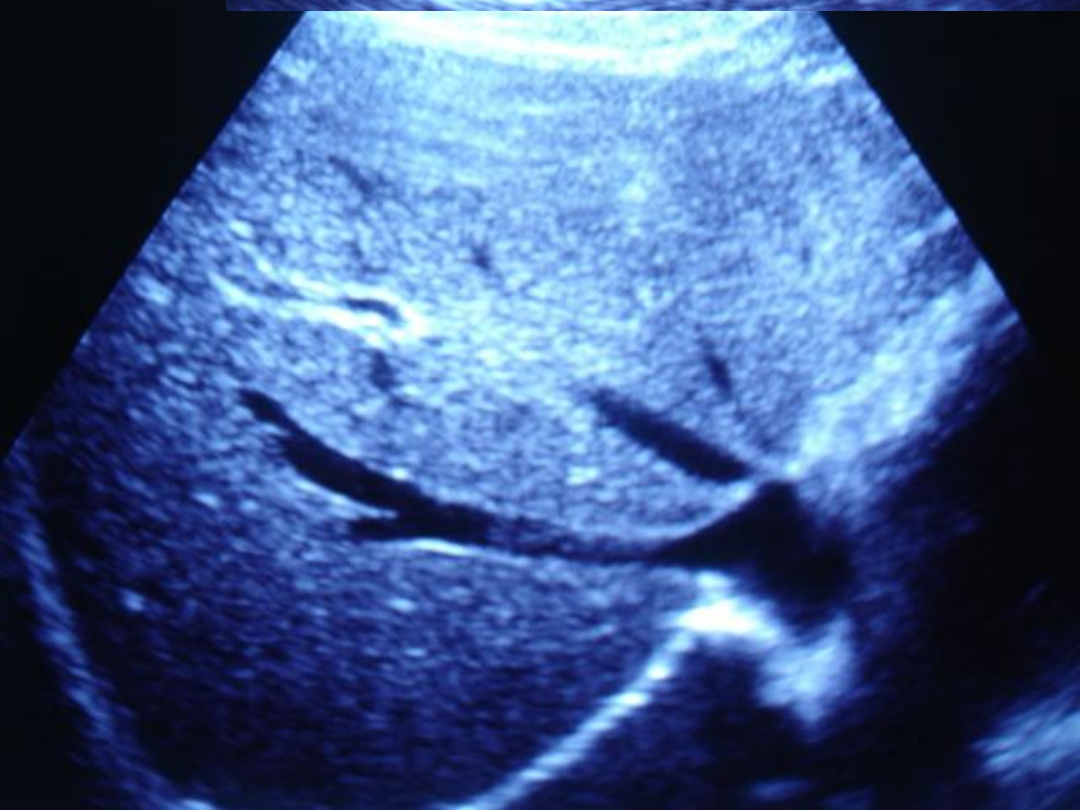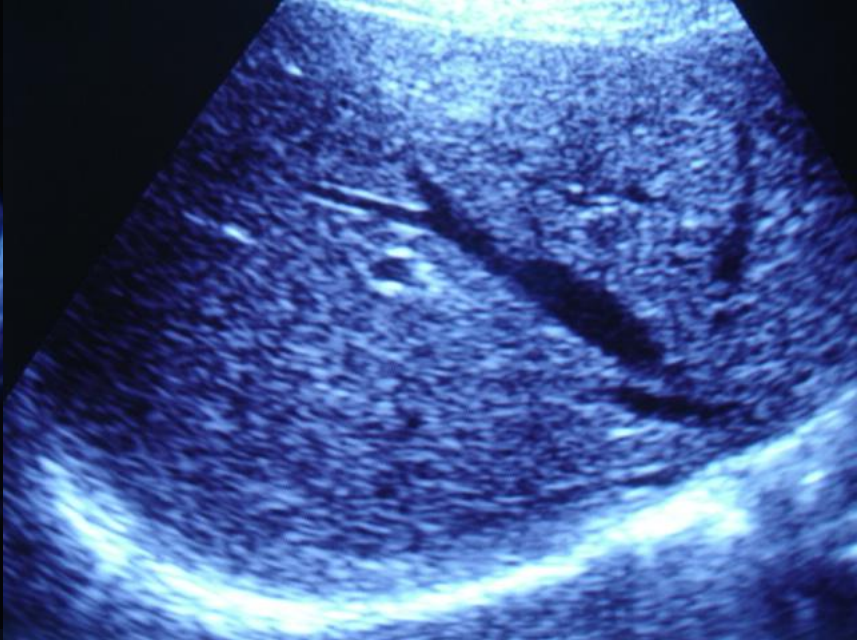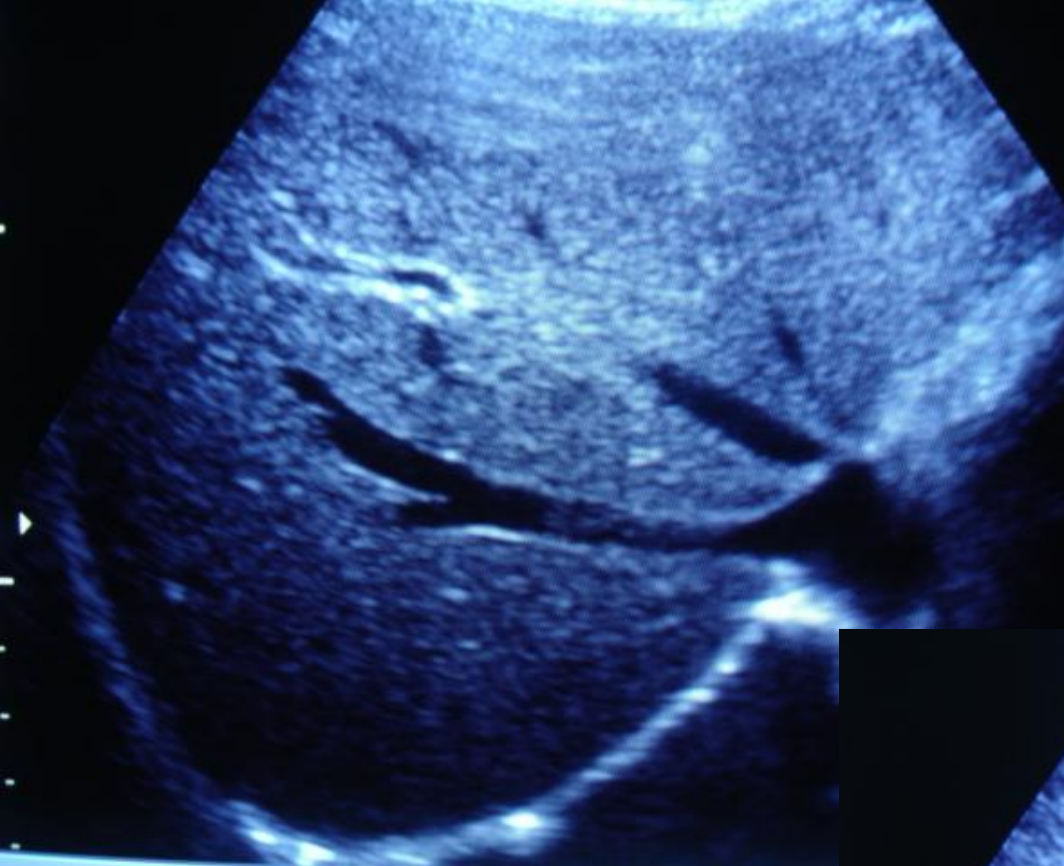## \* CONTRAINDICACIONES

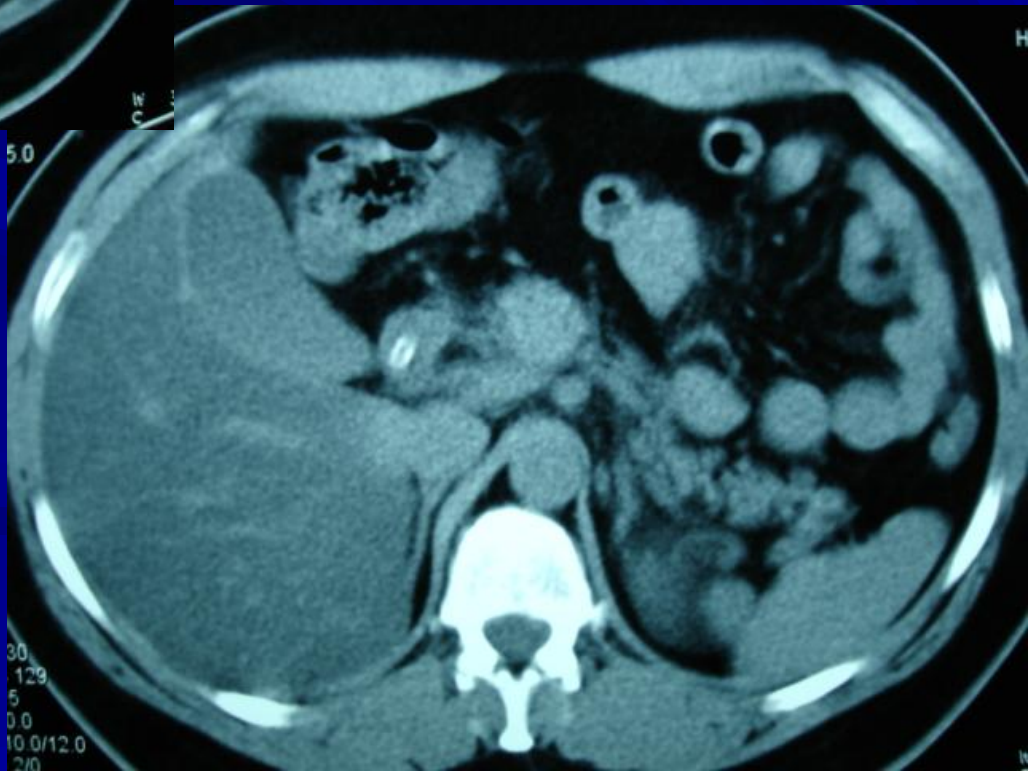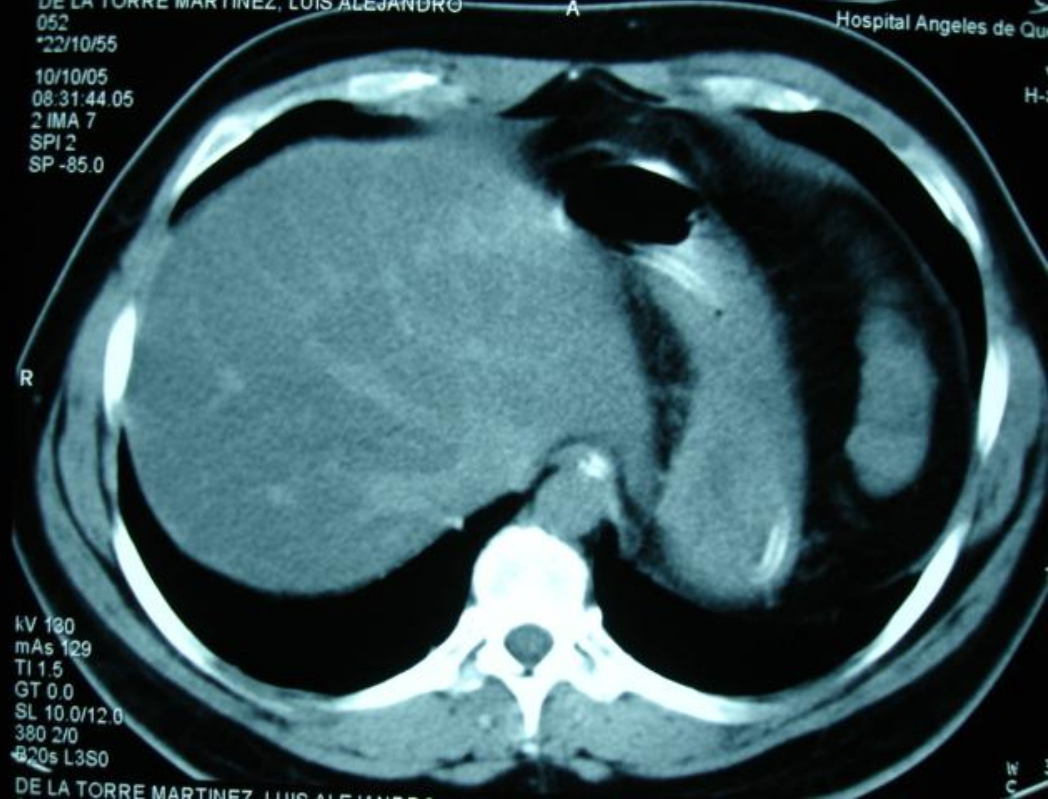NINGUNA

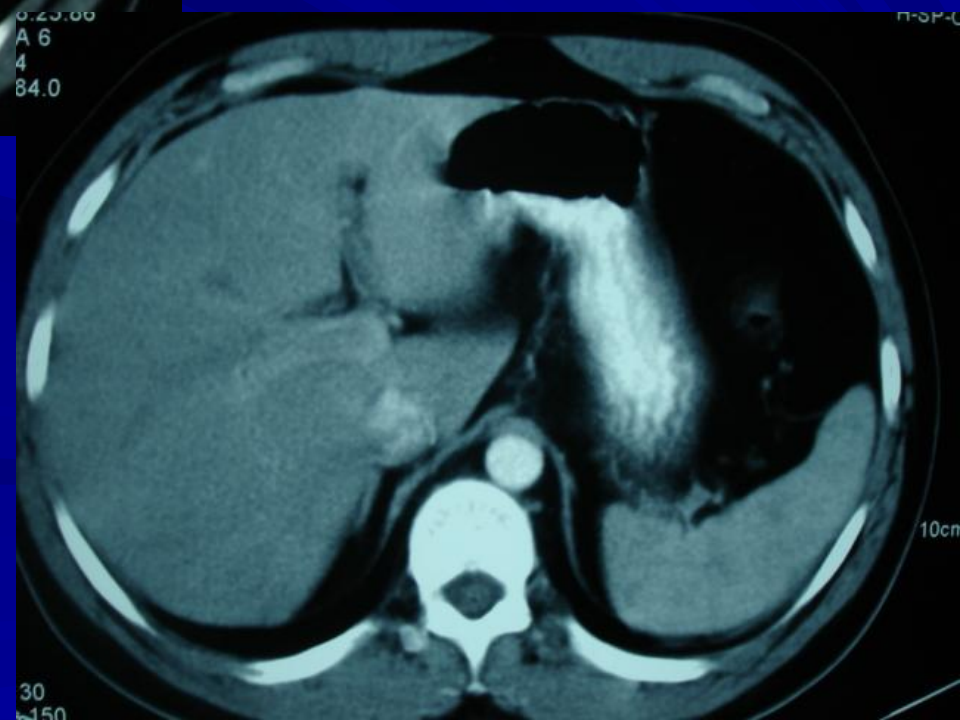
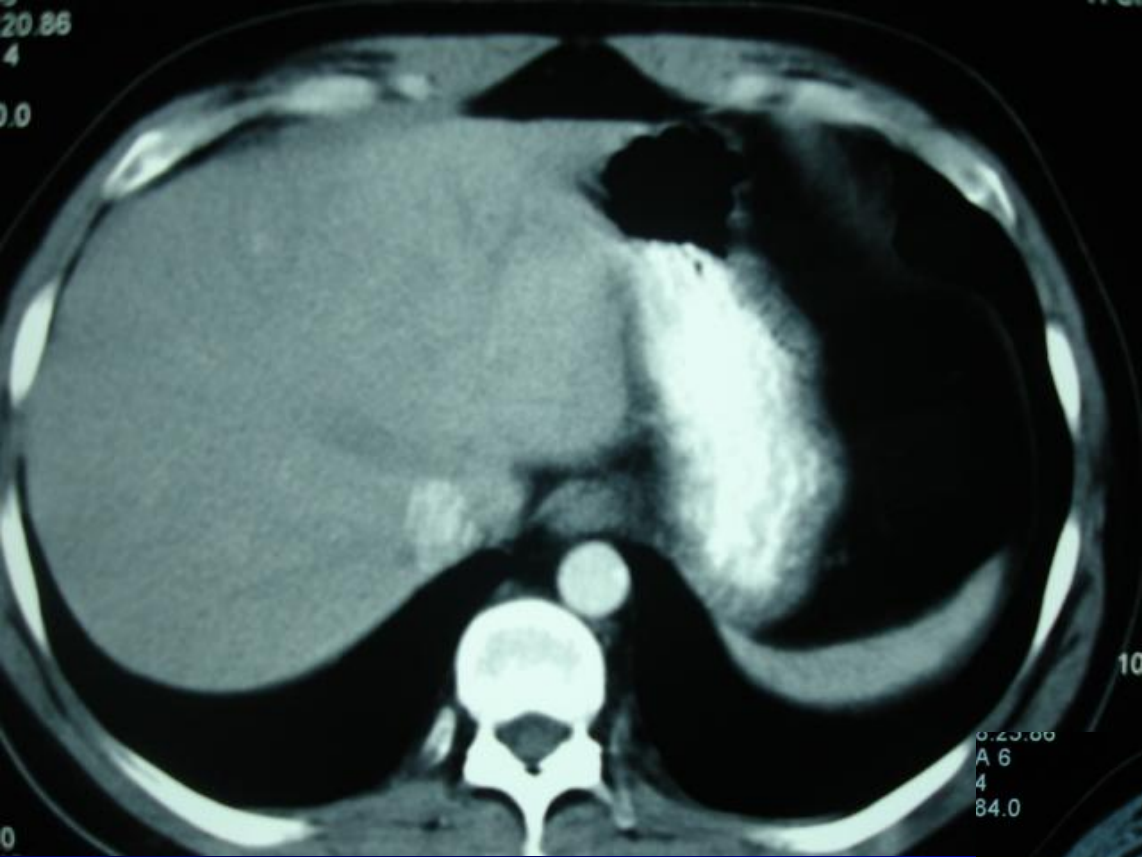






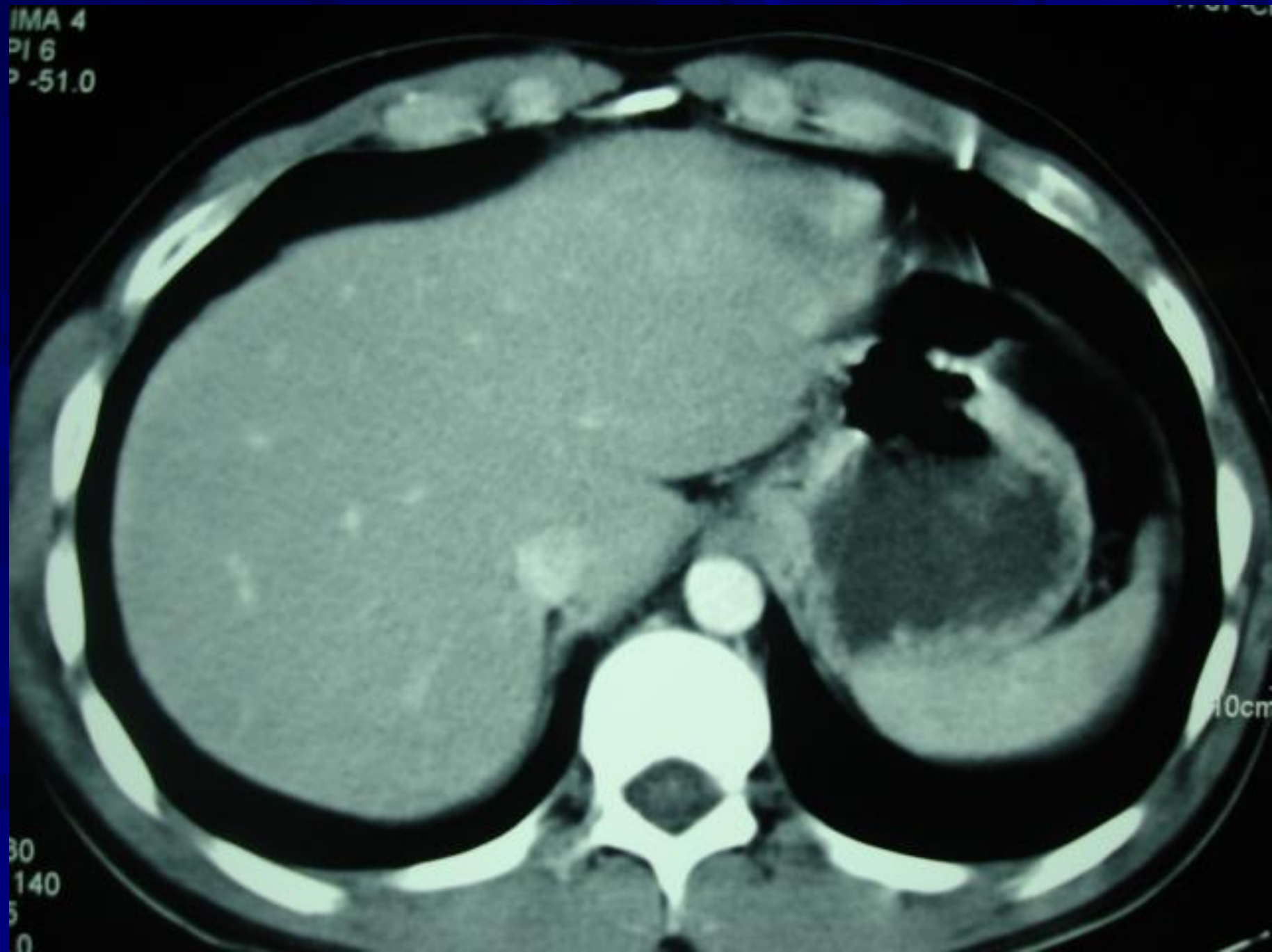






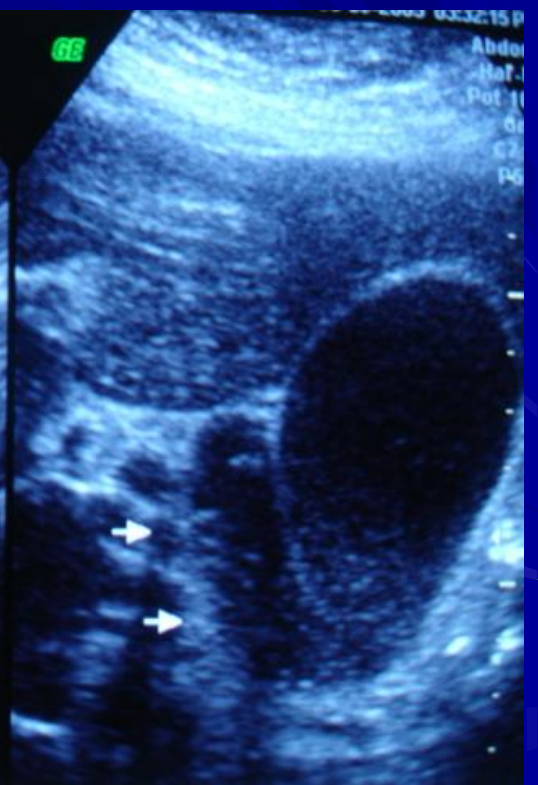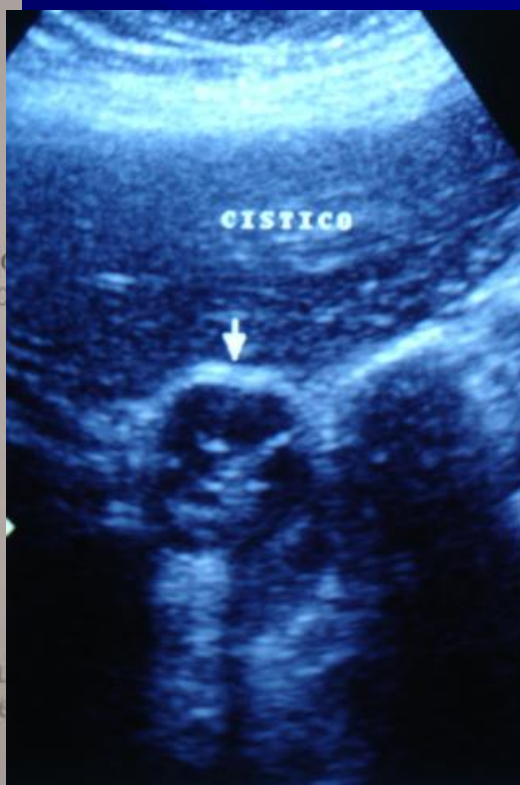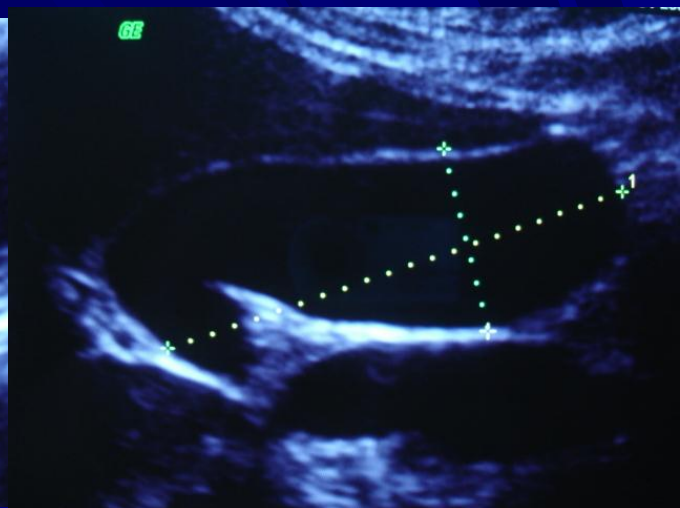
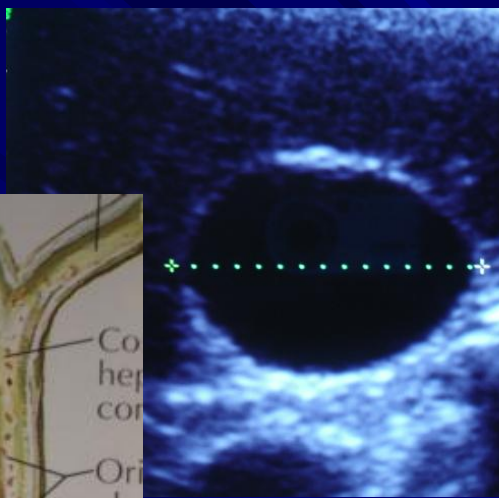
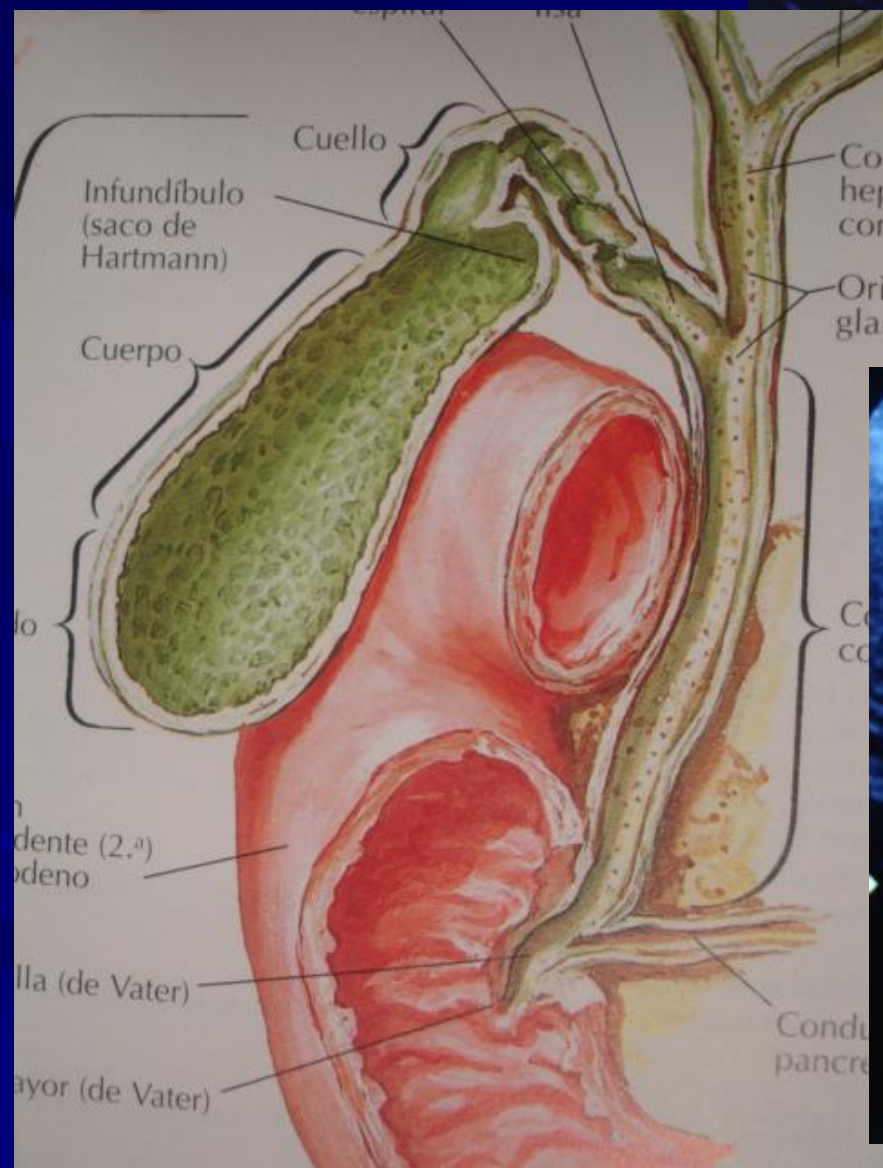


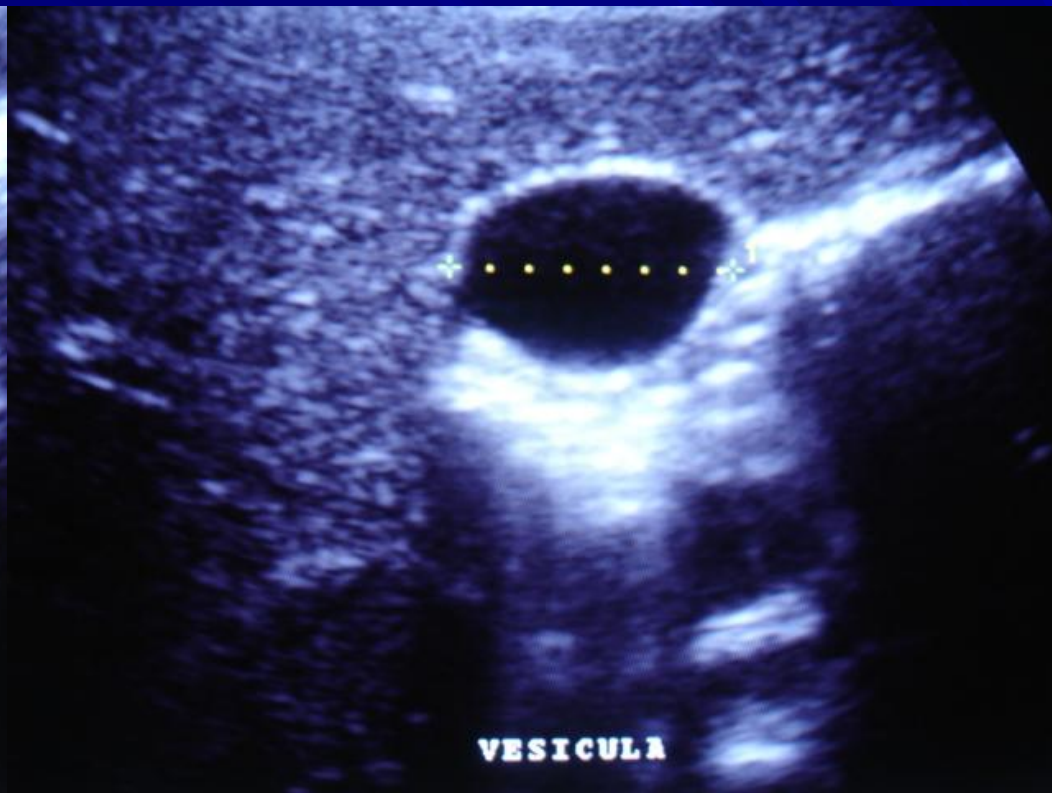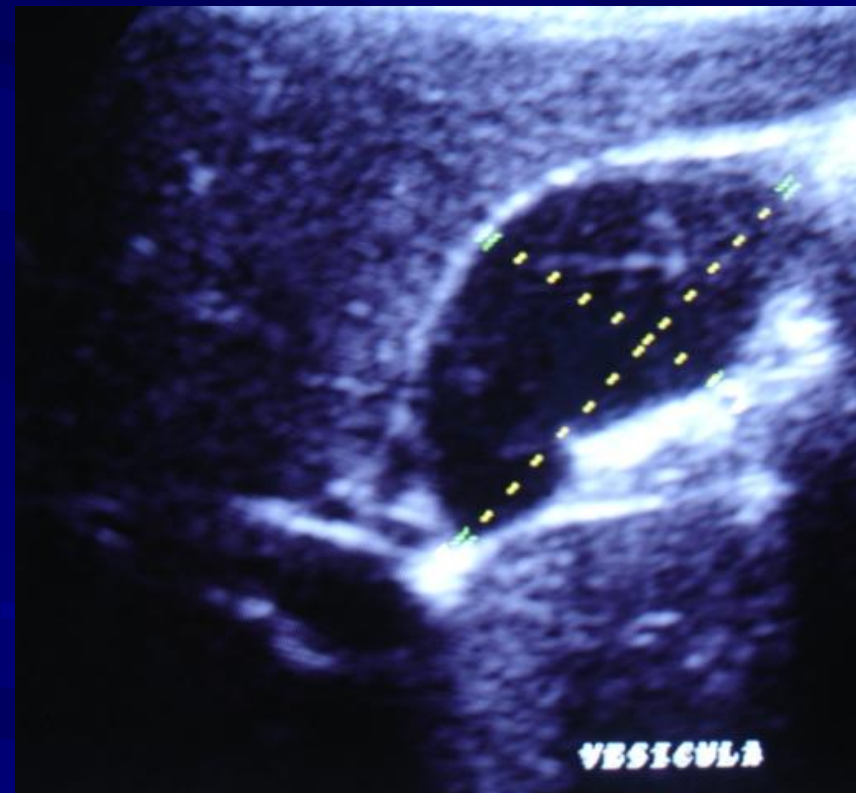IMA 4  
PI 6  
P -51.0

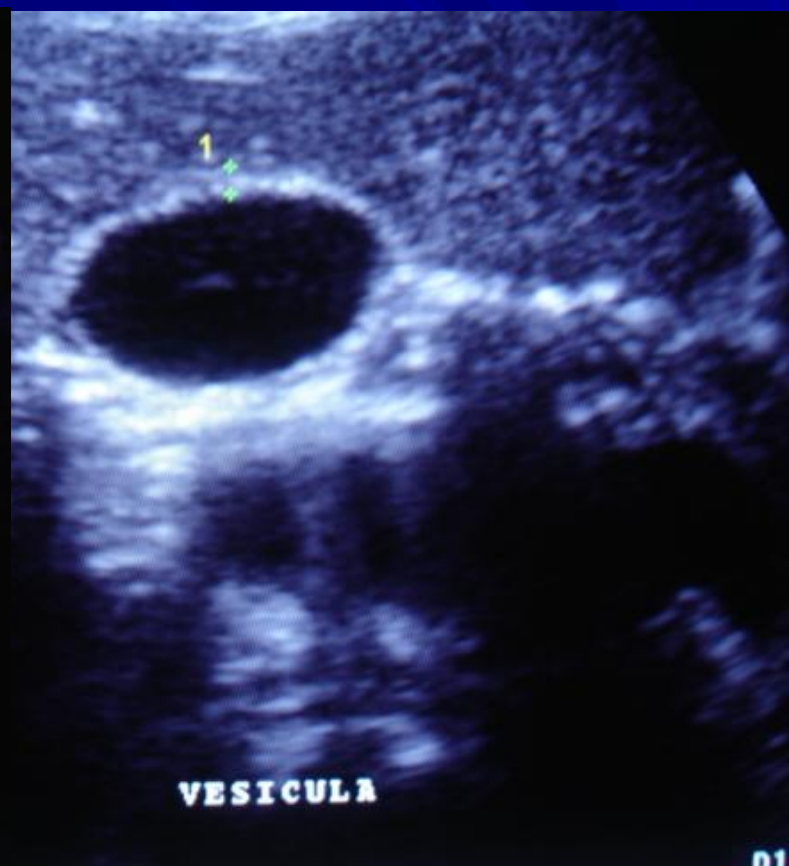
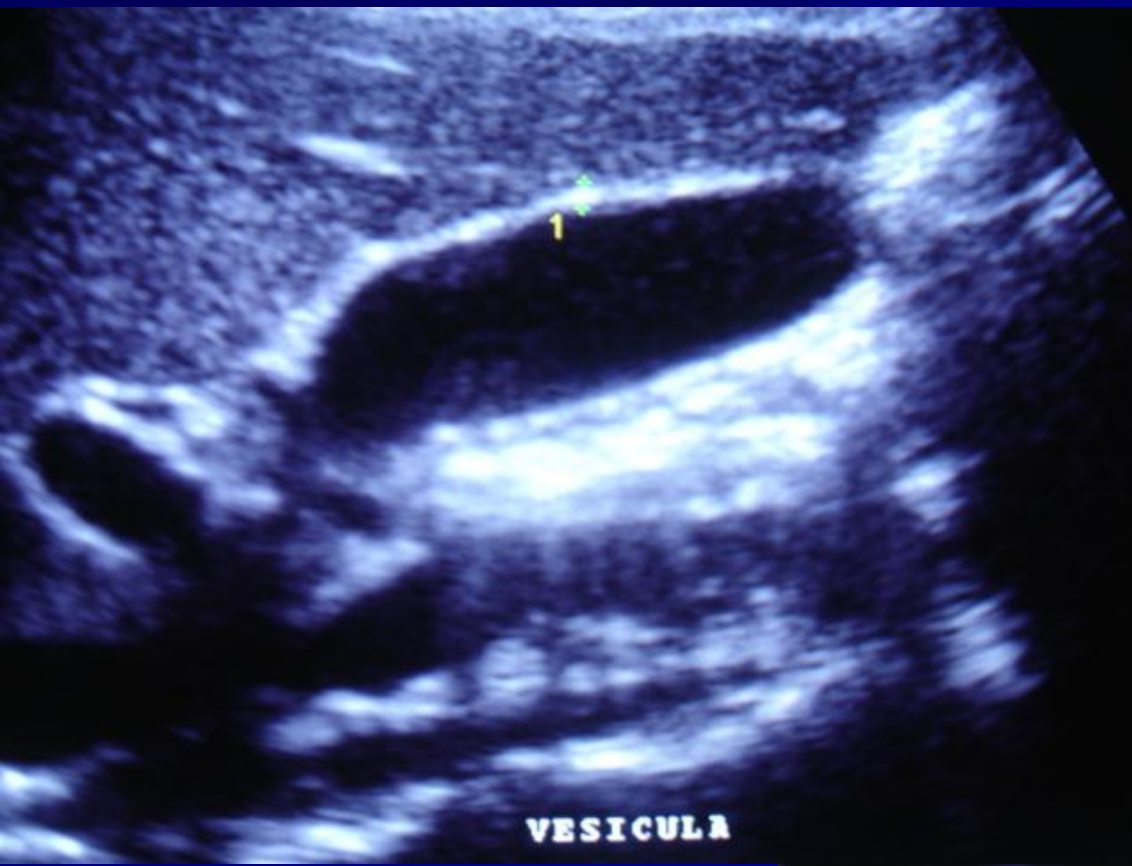
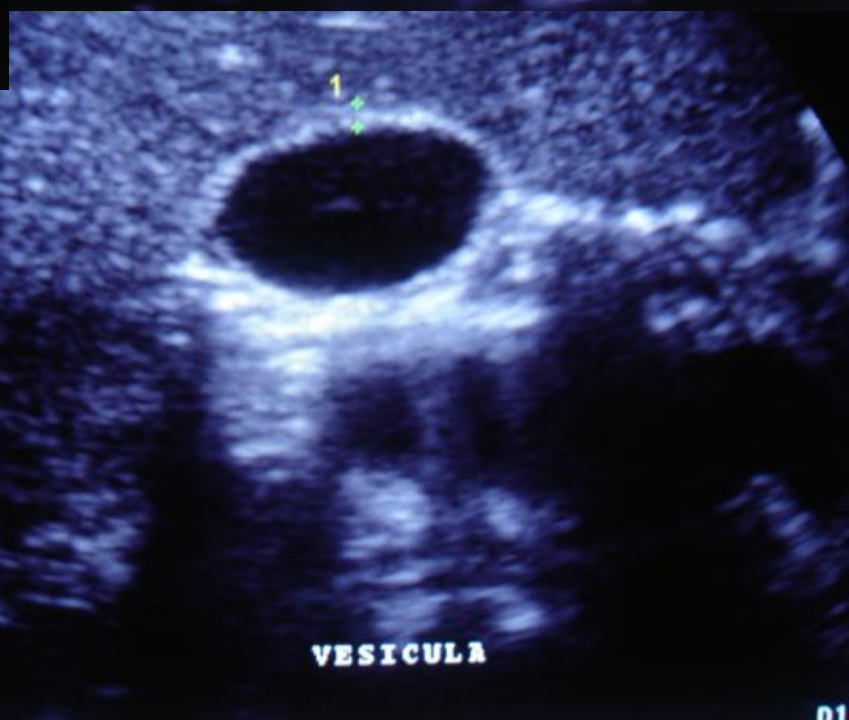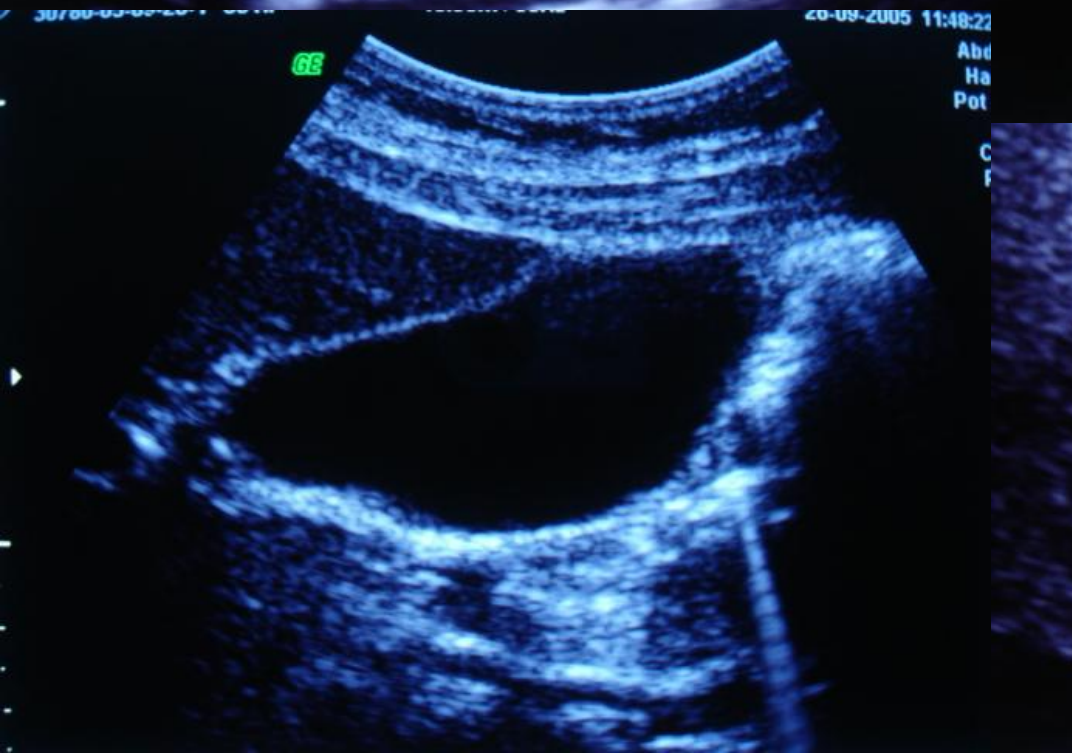
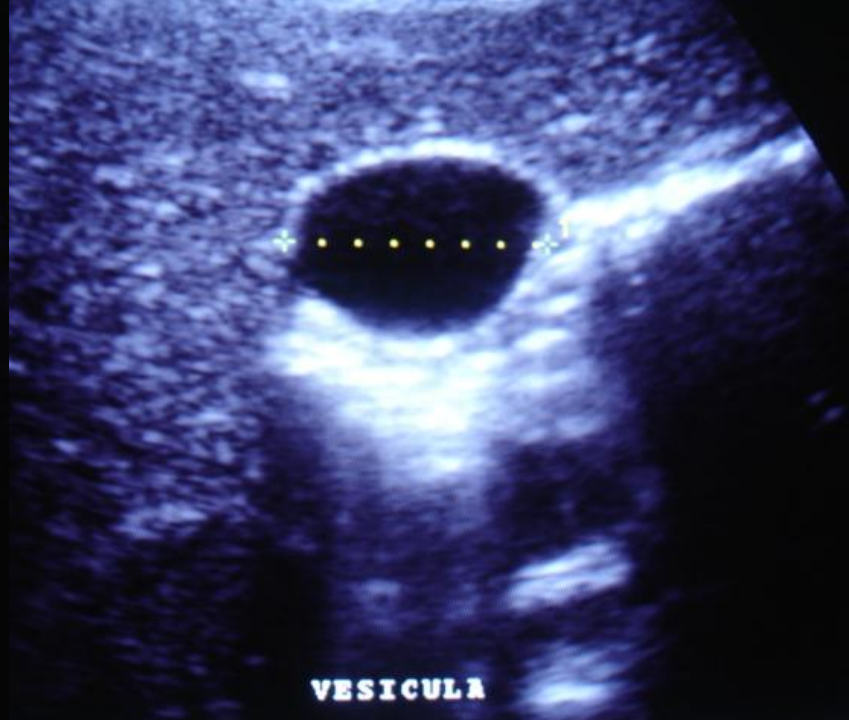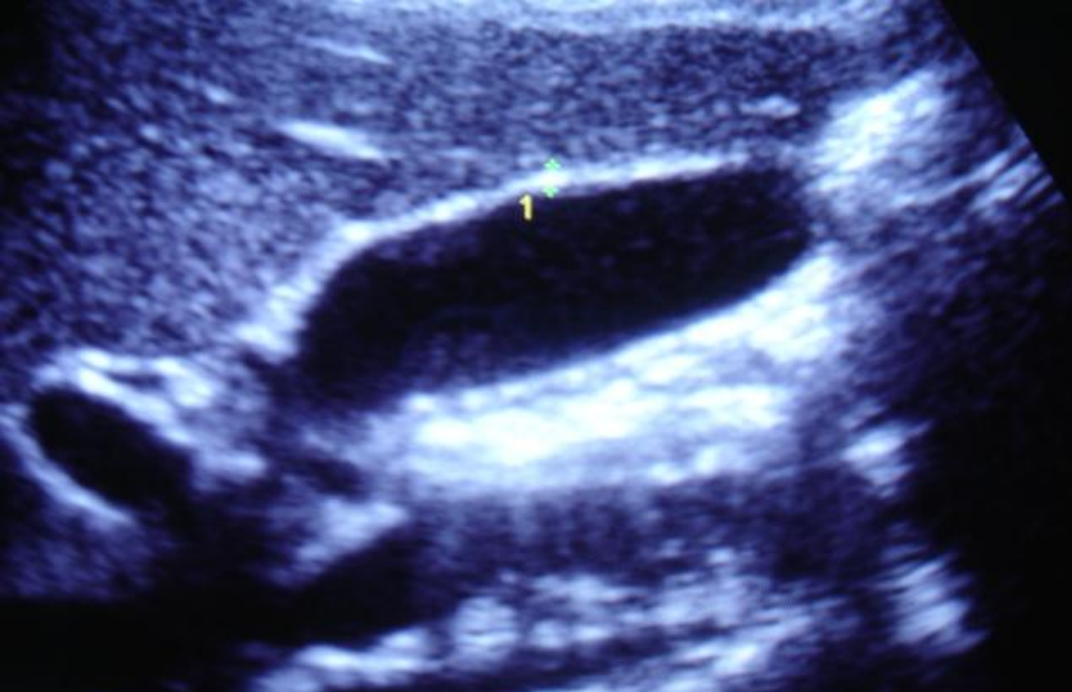10cm

30  
140  
5  
0

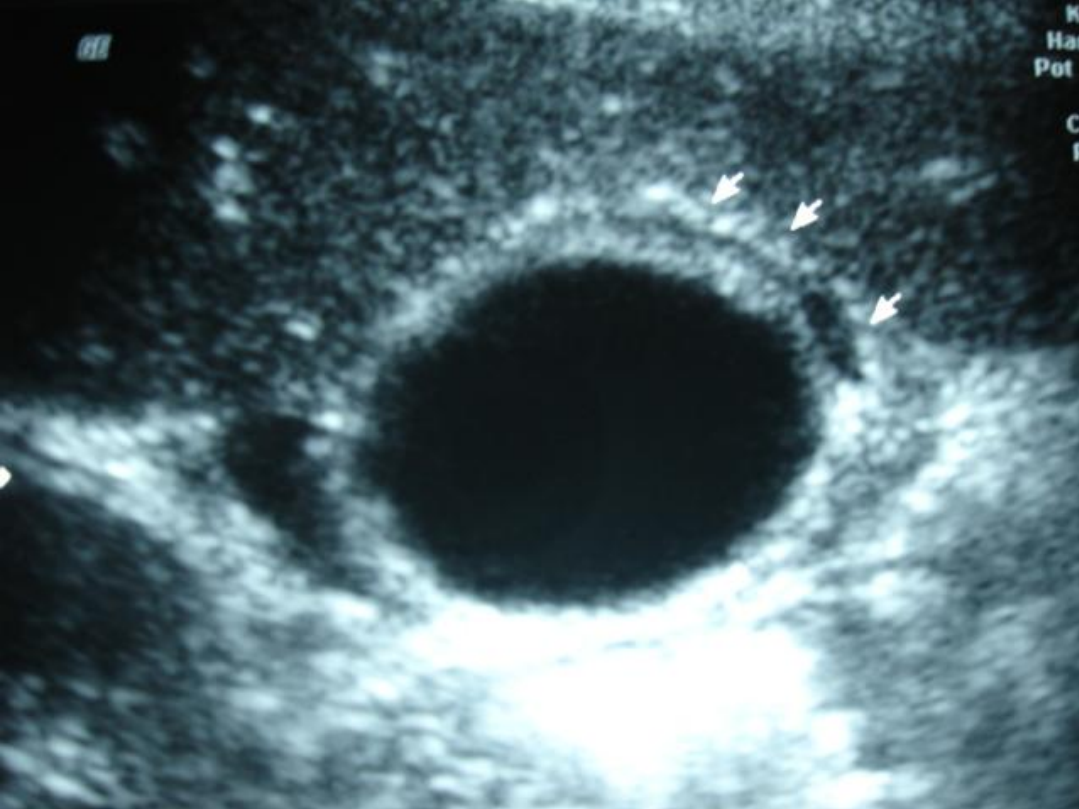




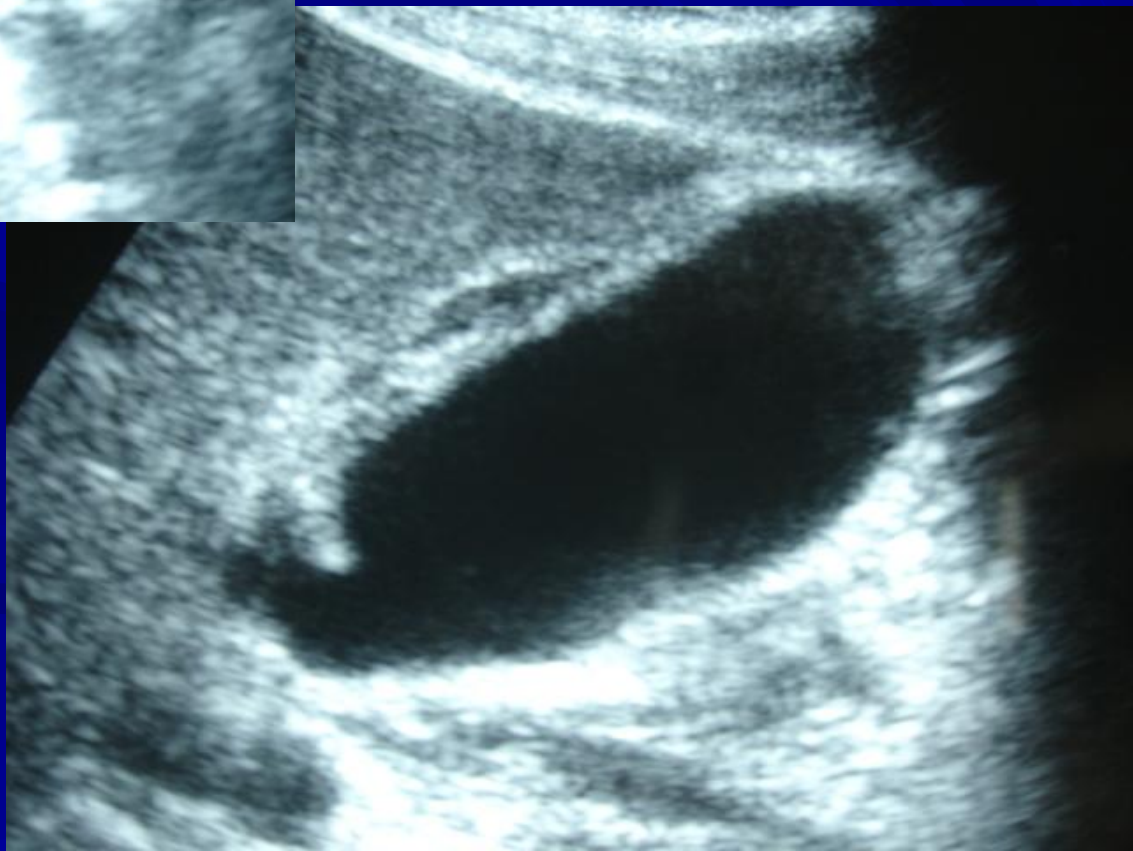

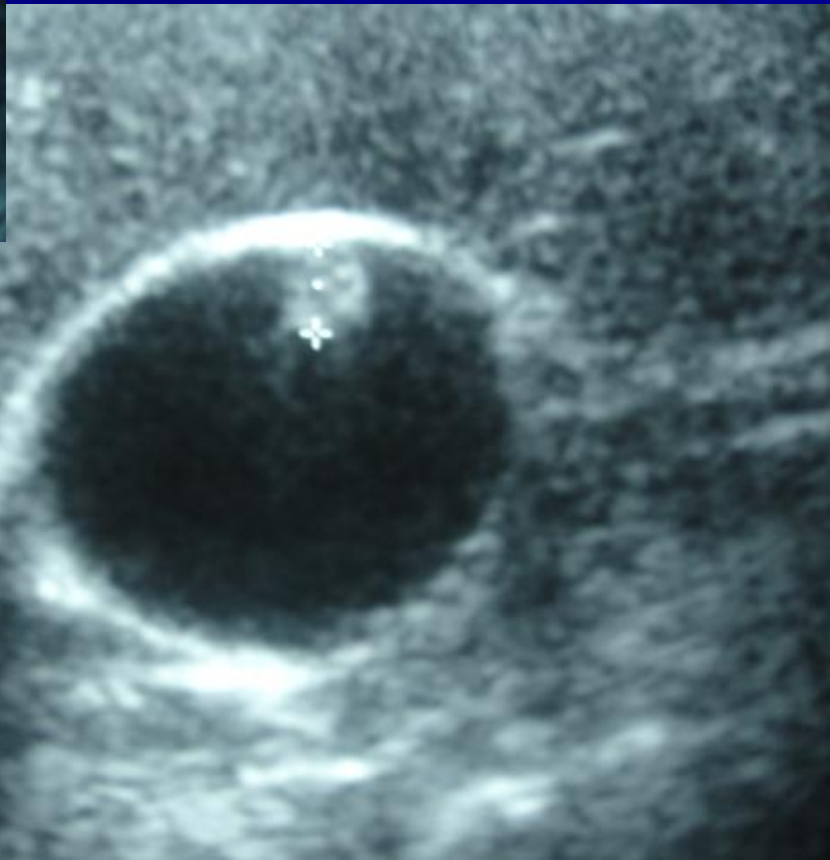

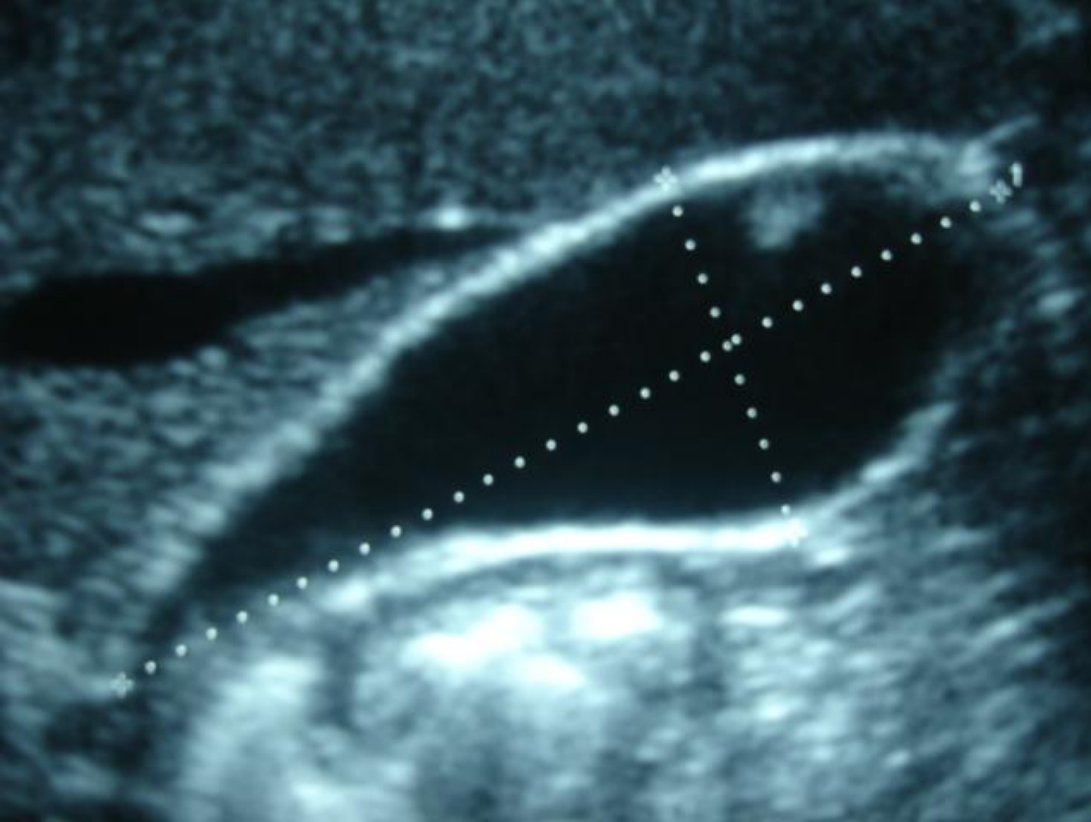
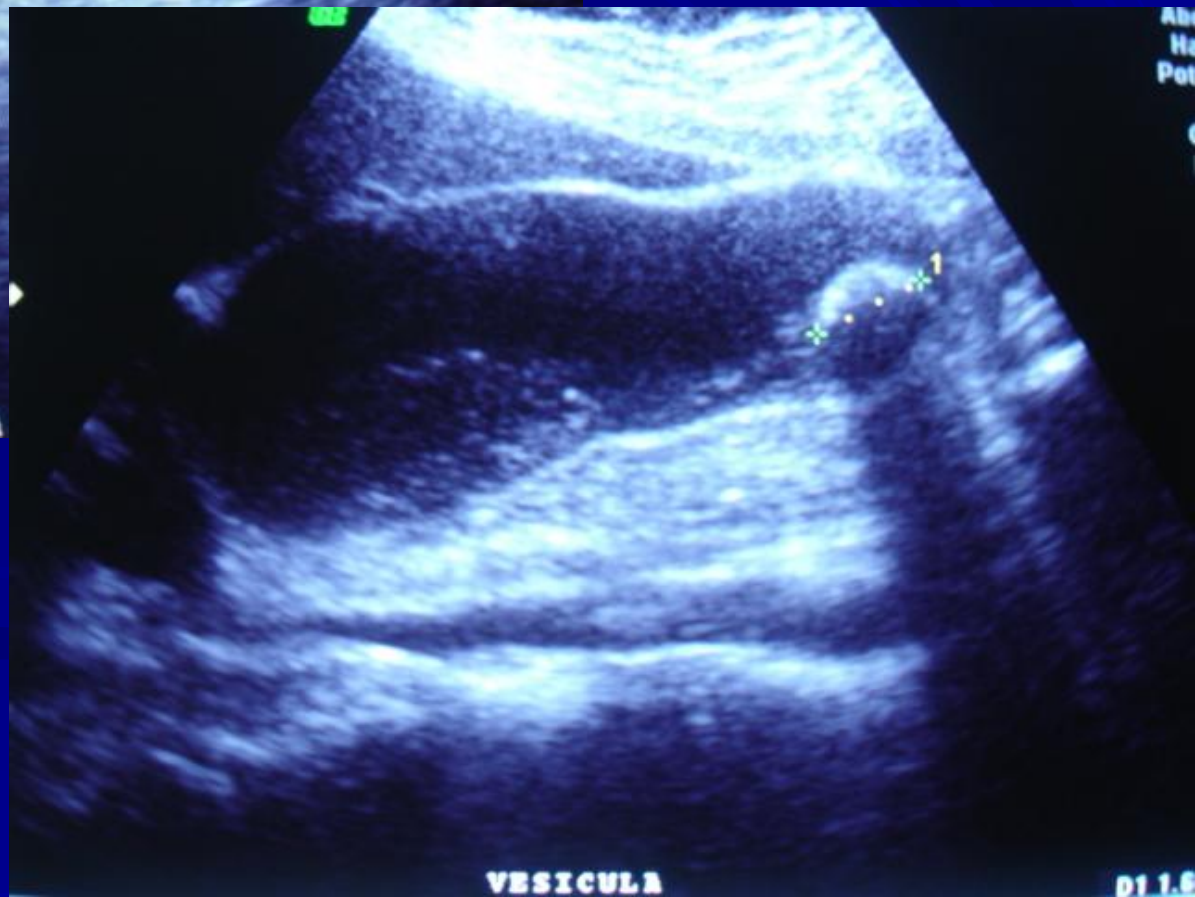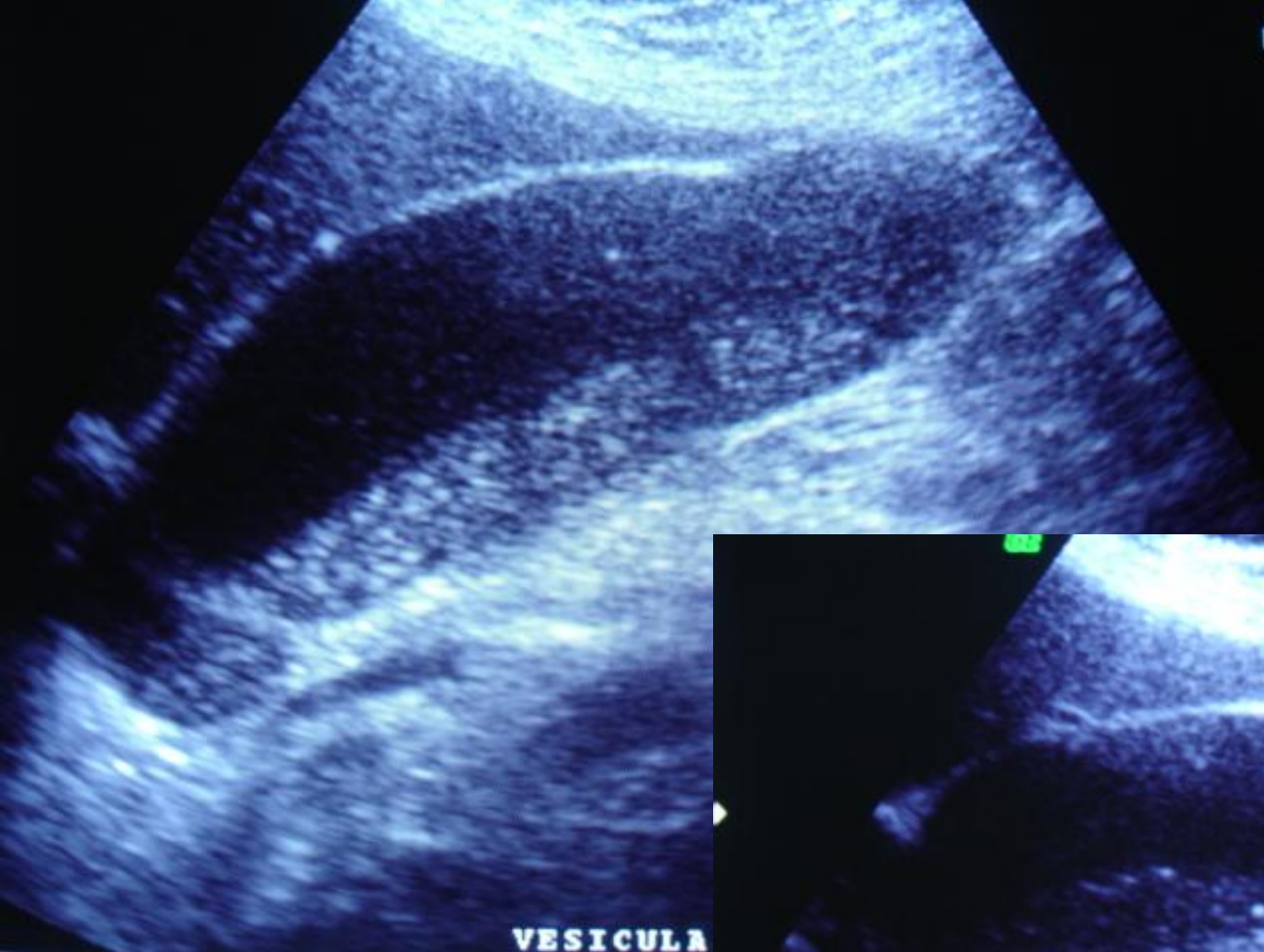
30700-03-06-001 20-09-2005 11:48:22  
Abd  
Ha  
Pot  
C  
F



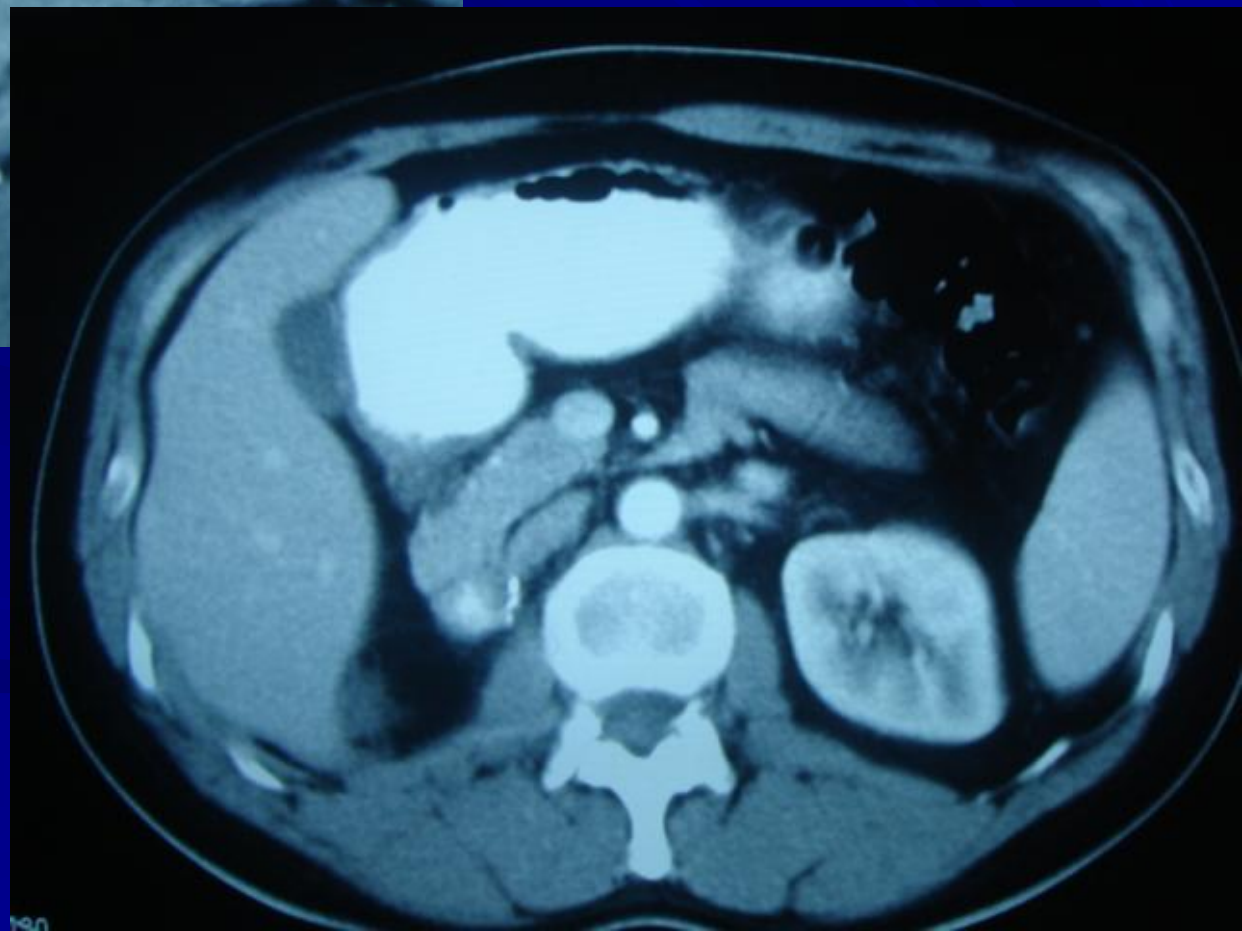
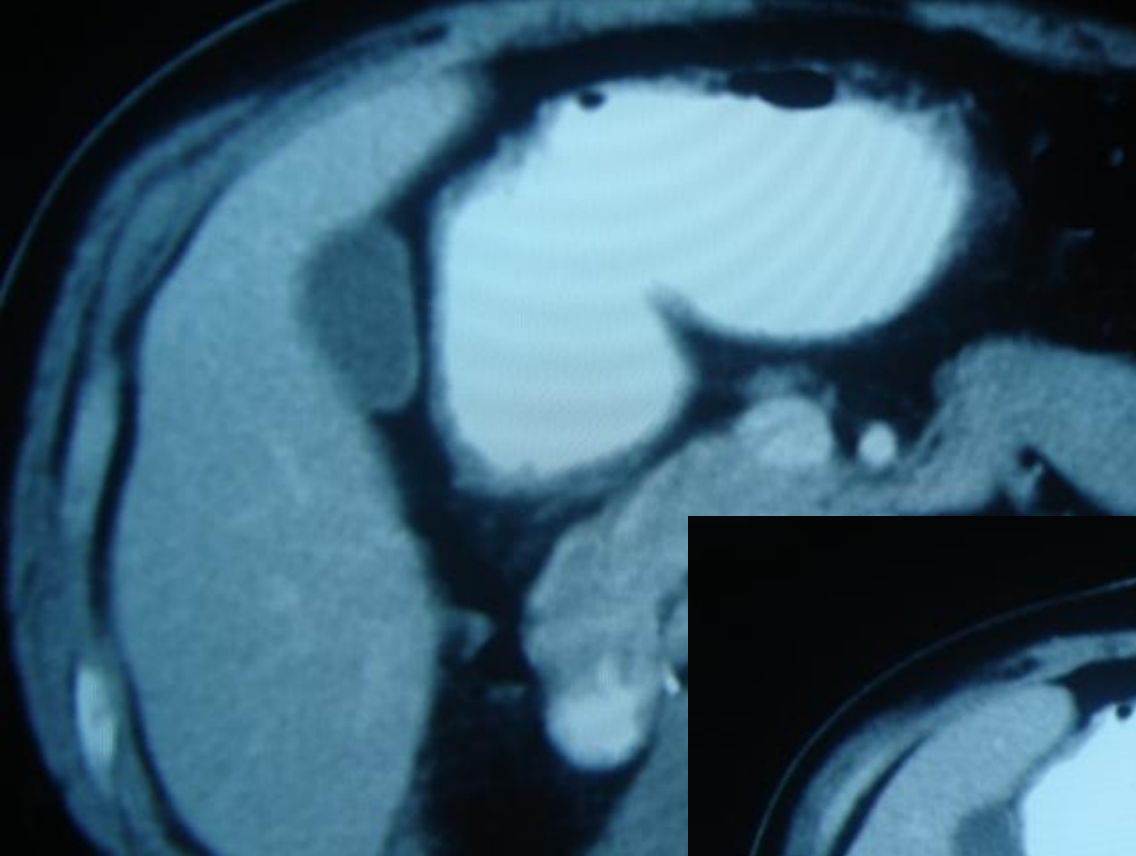
K  
Hal  
Pot  
C  
F

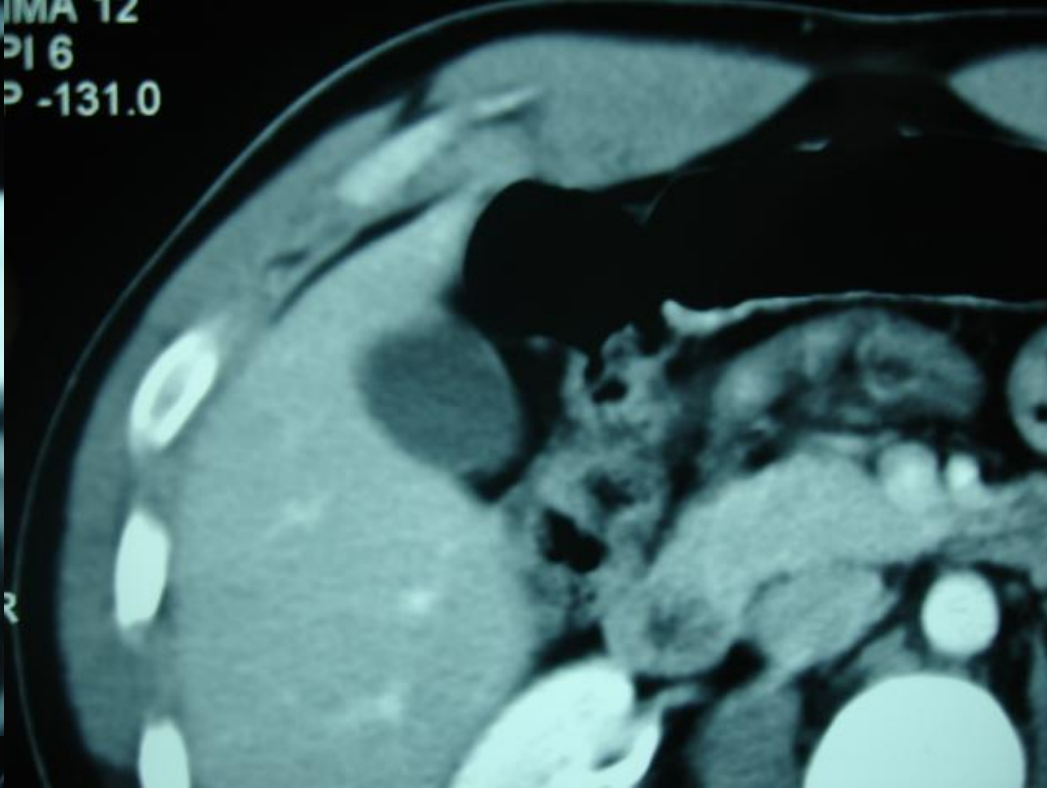
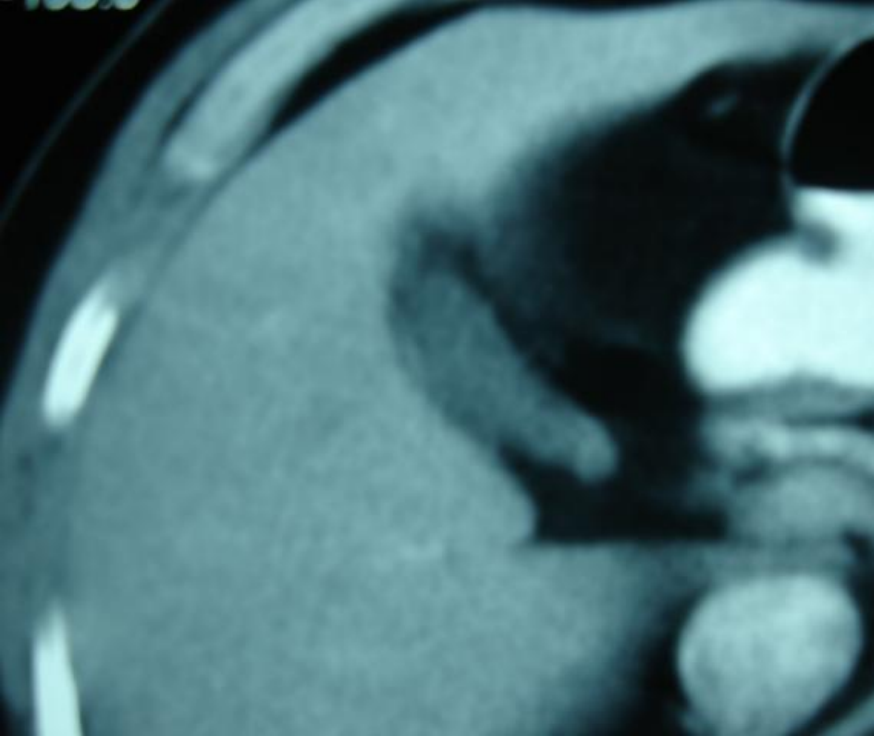




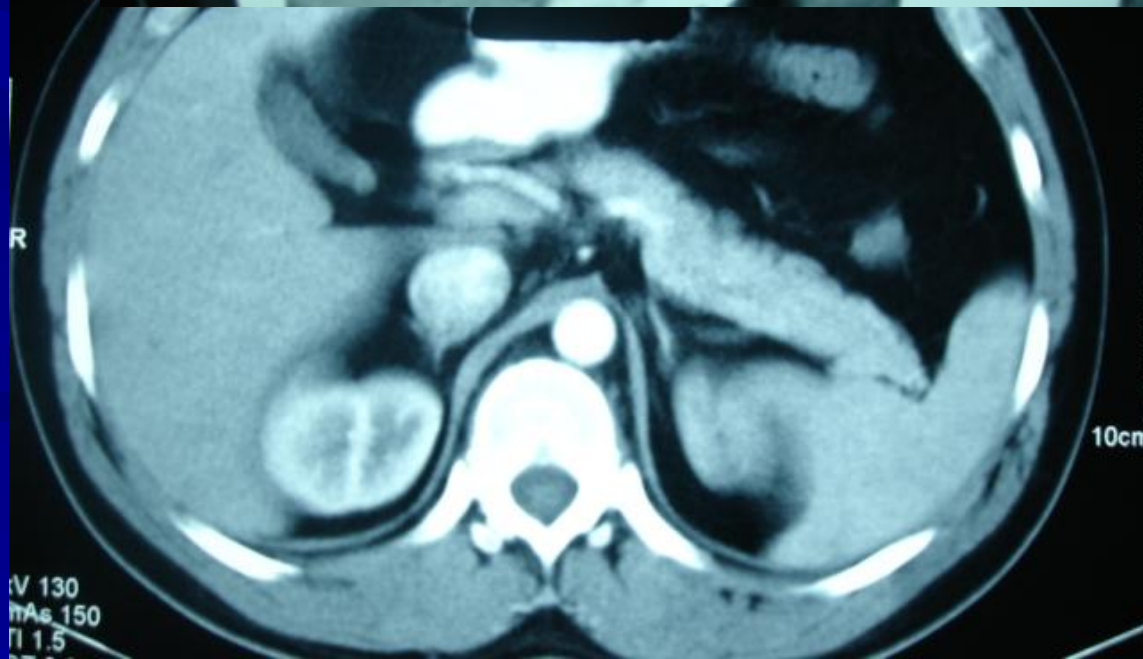

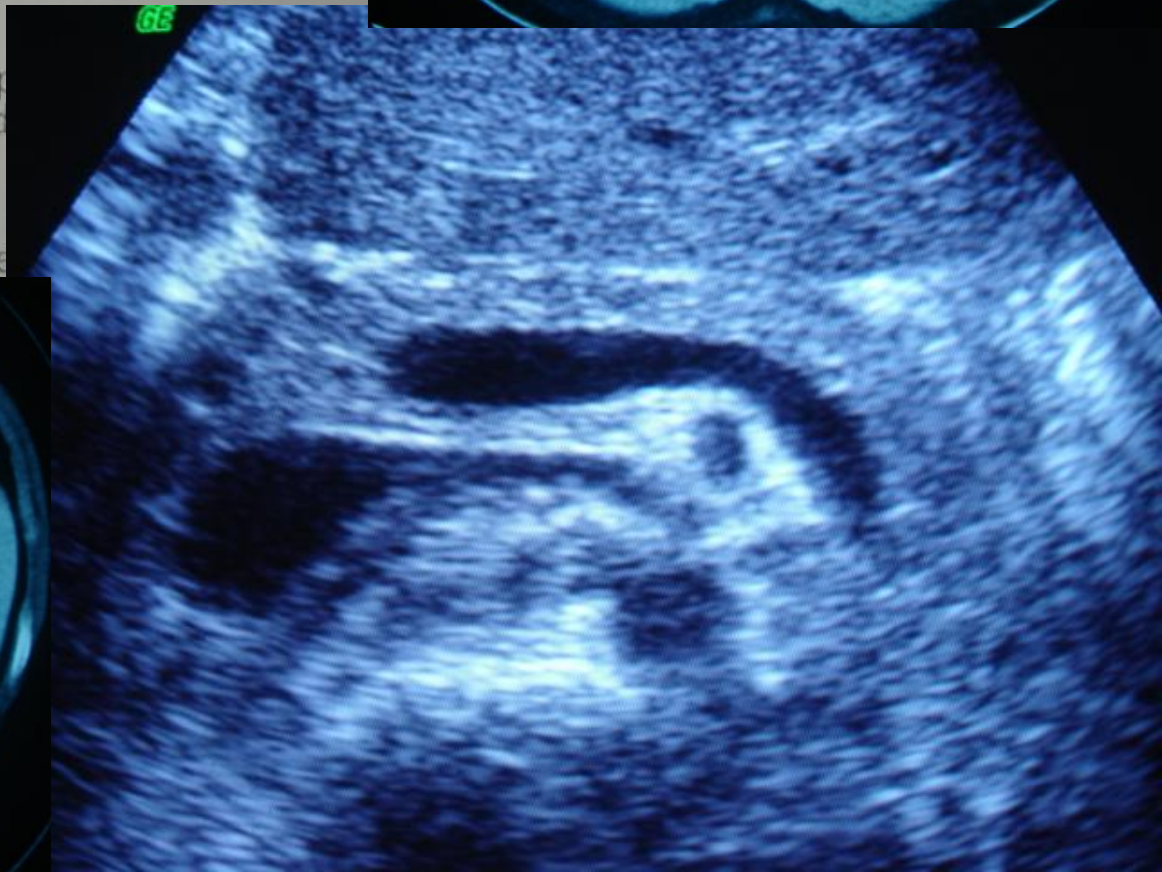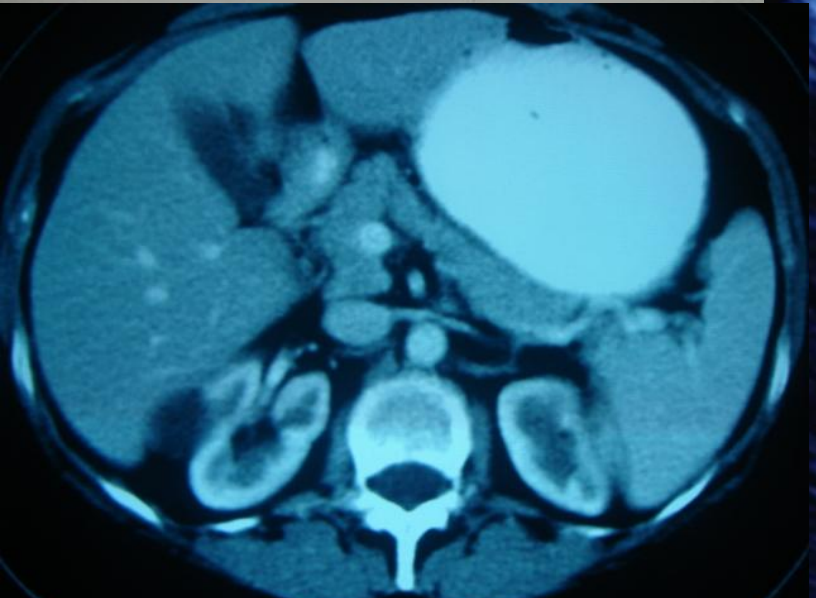
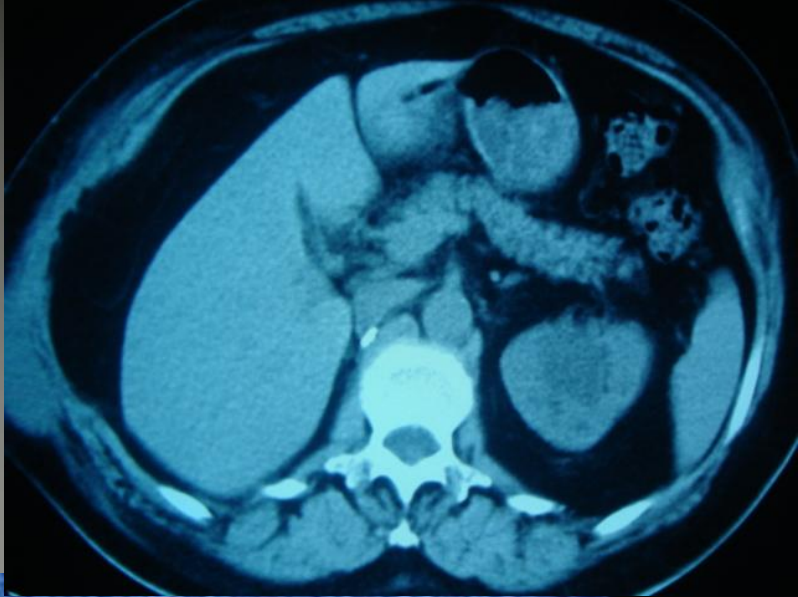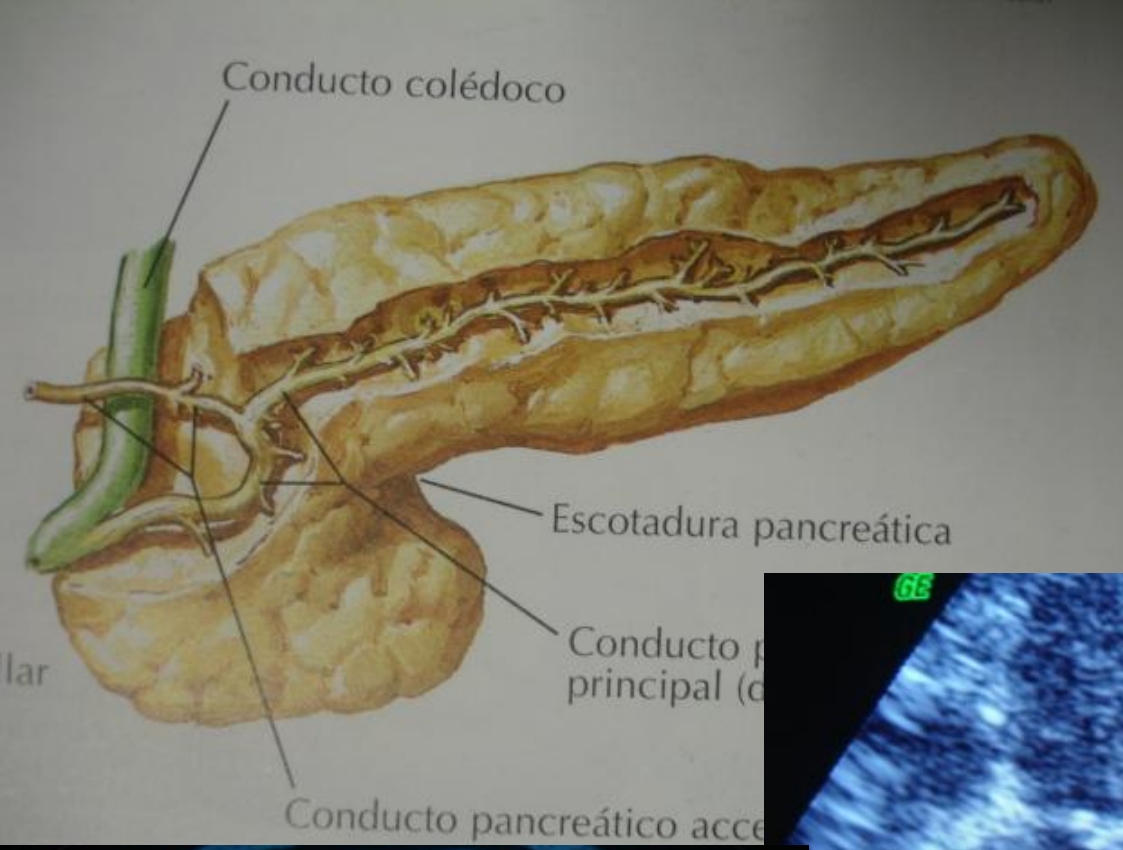




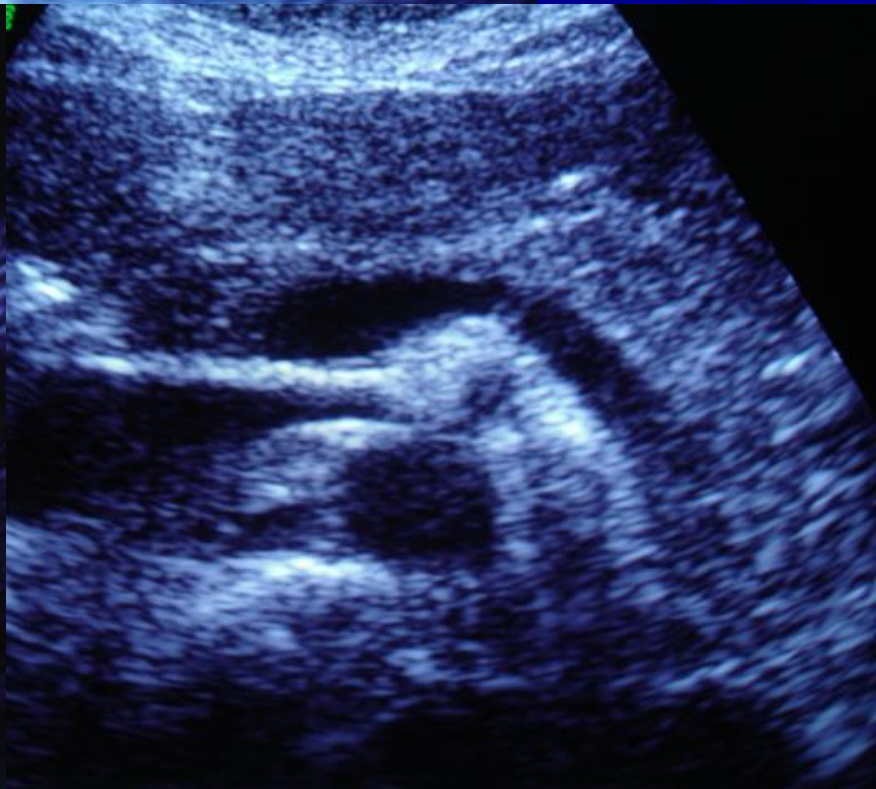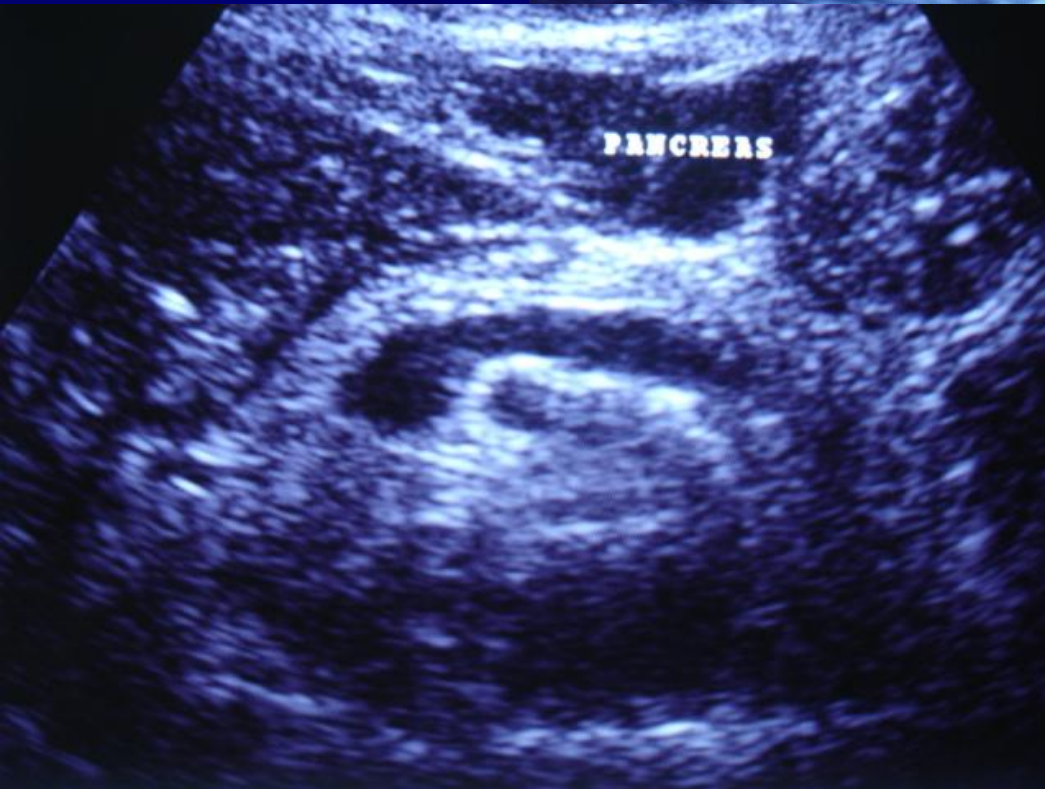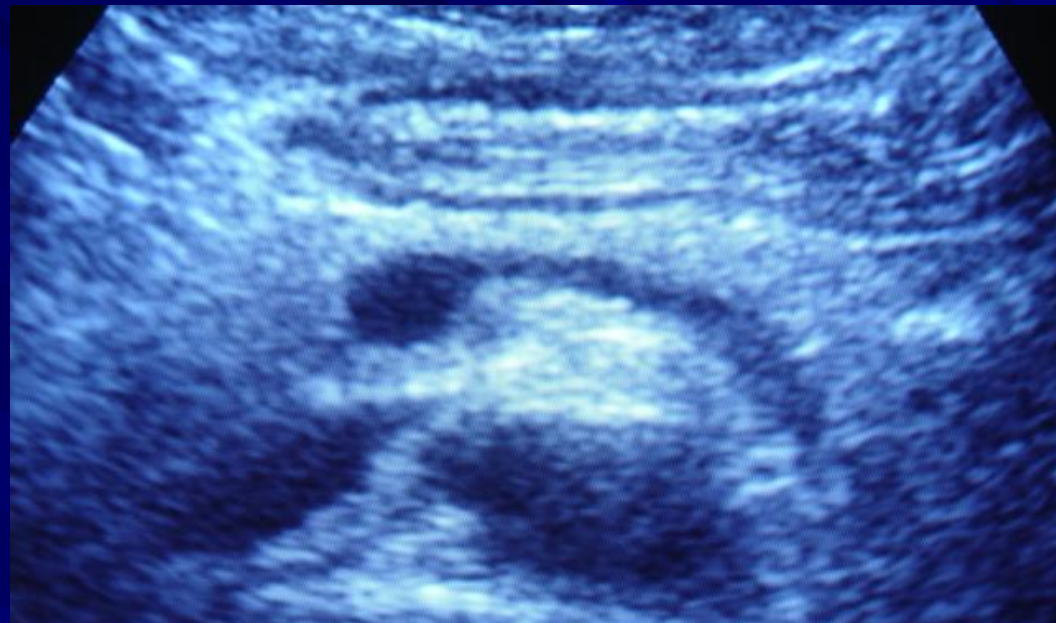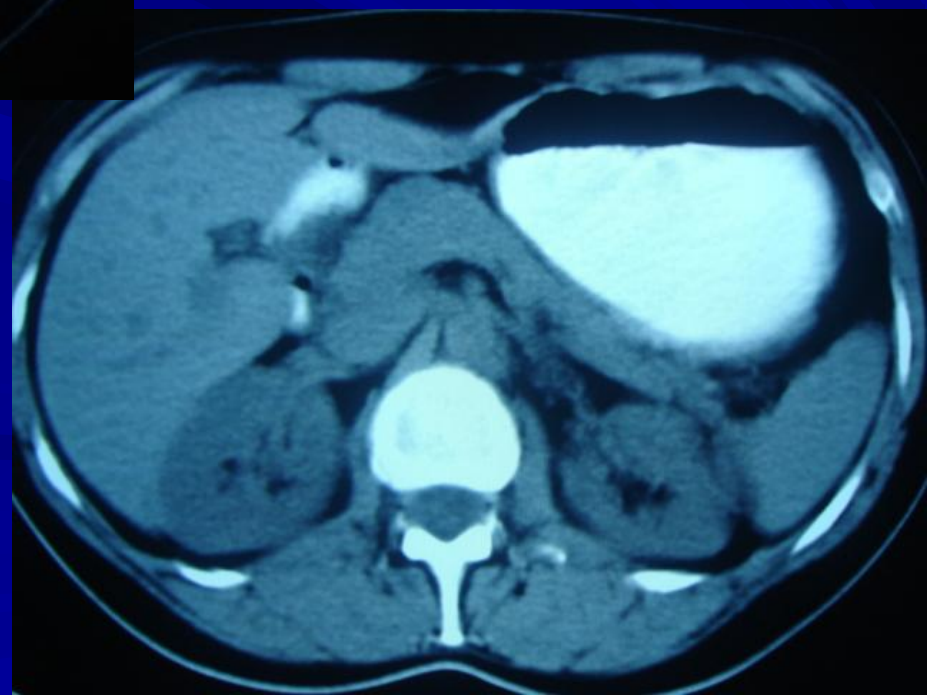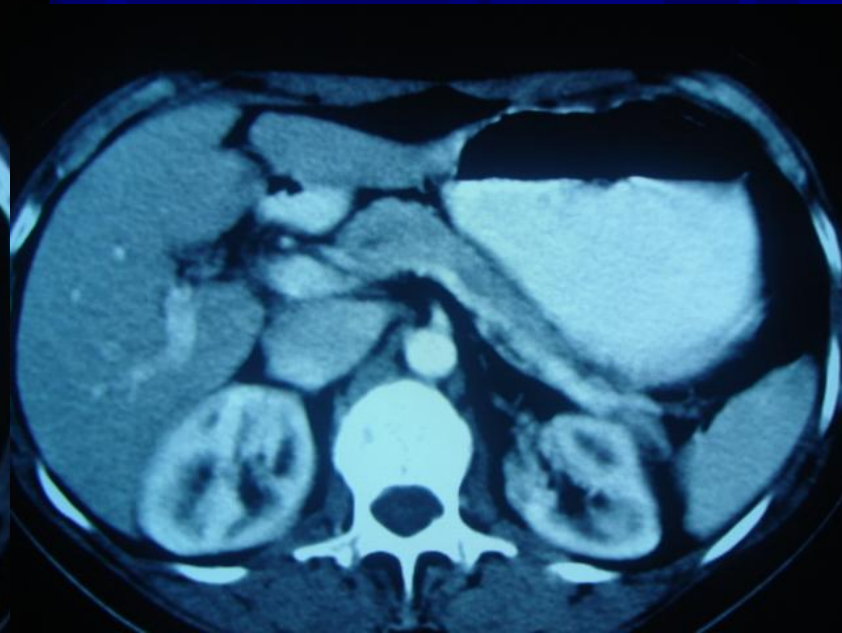


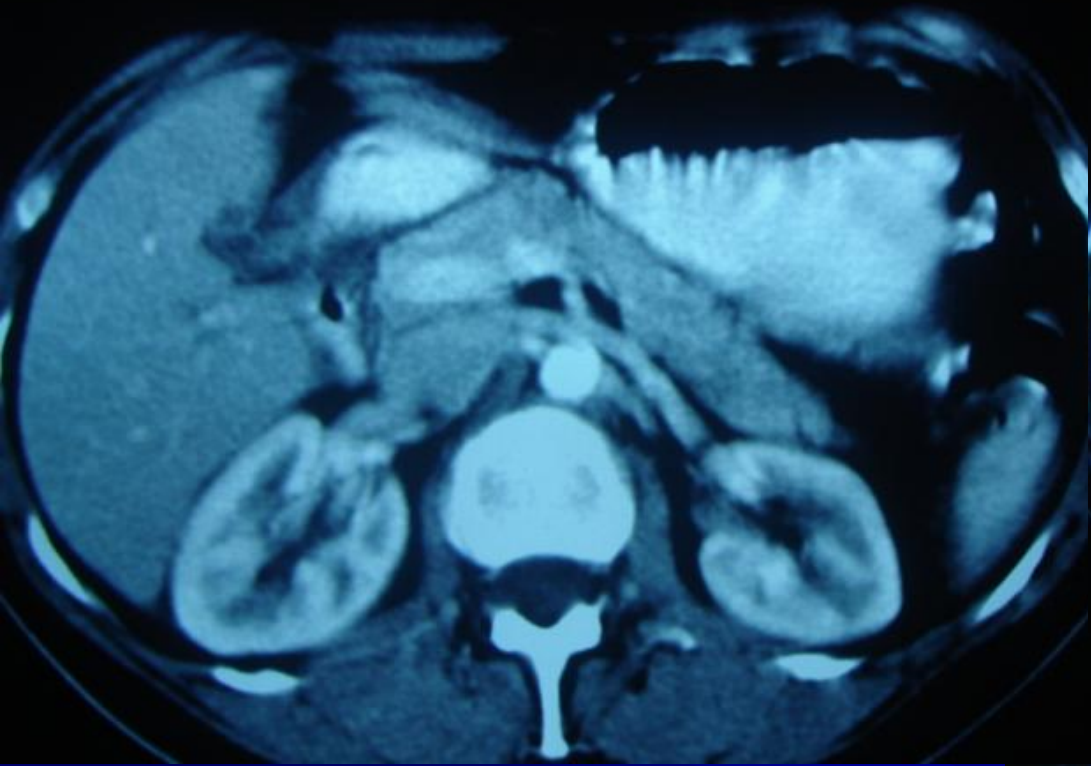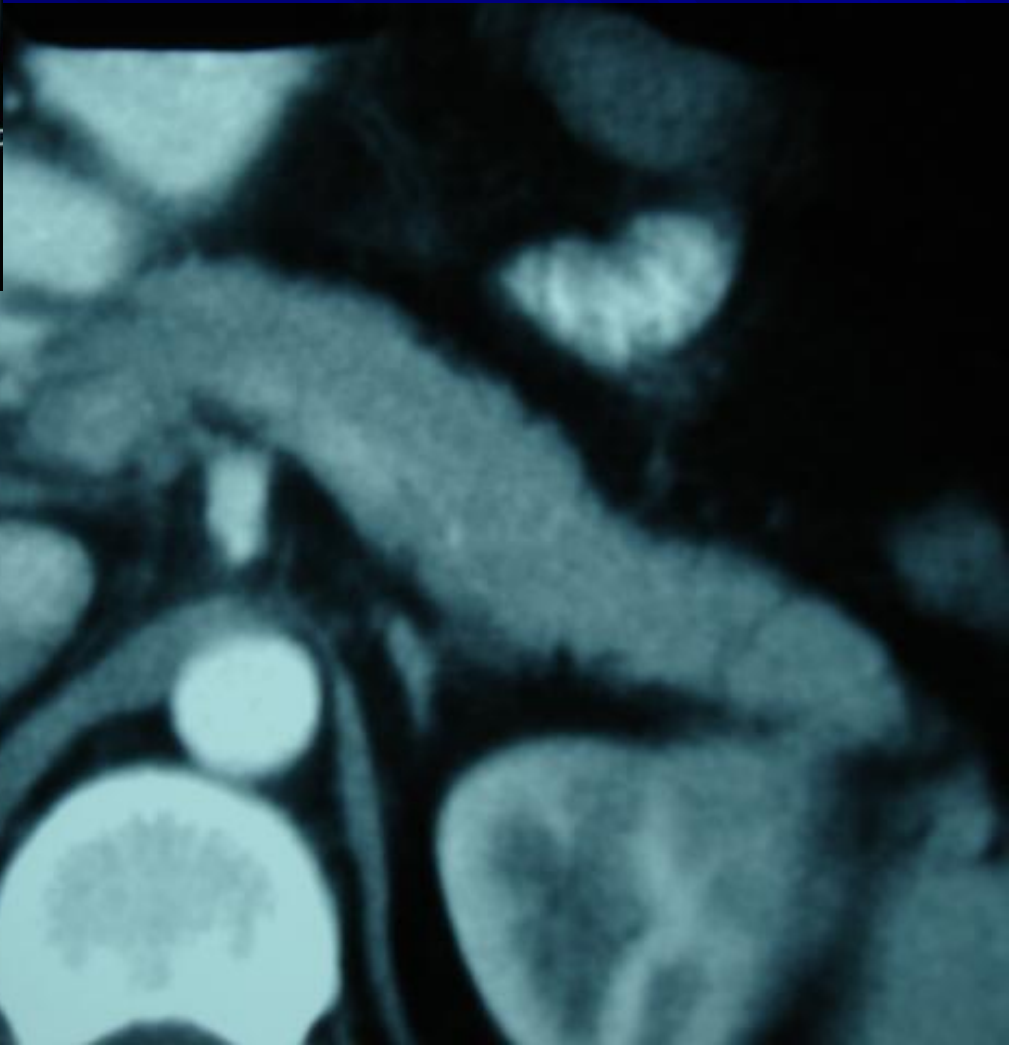
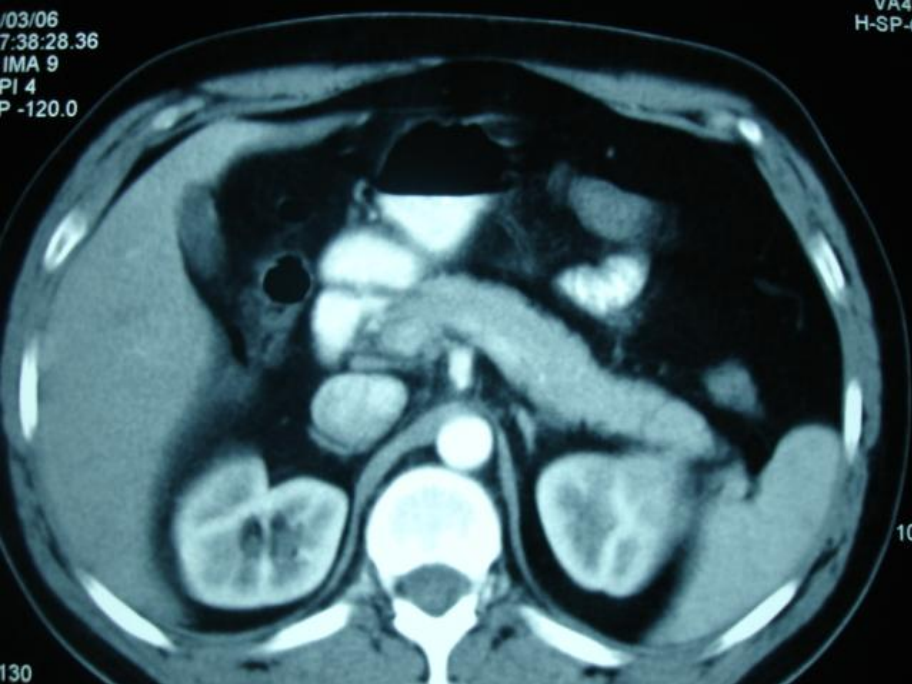# VESICULA BILIAR

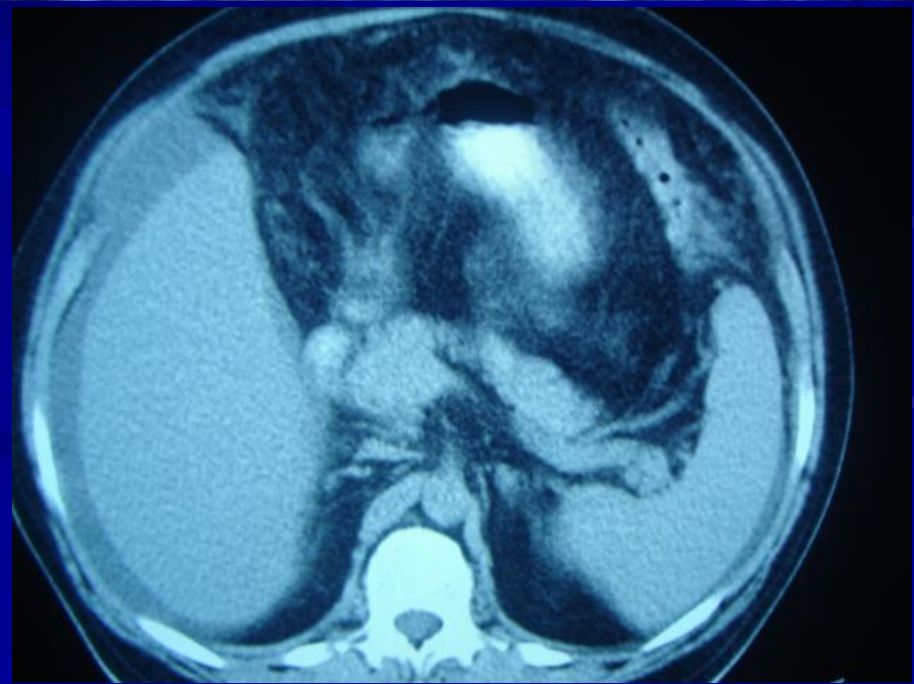
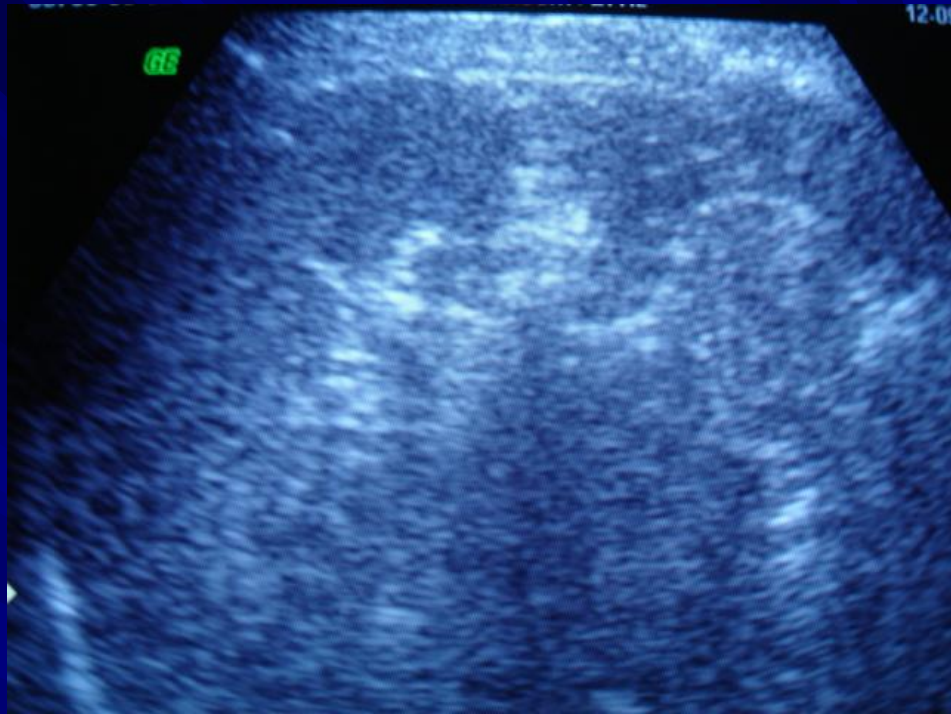
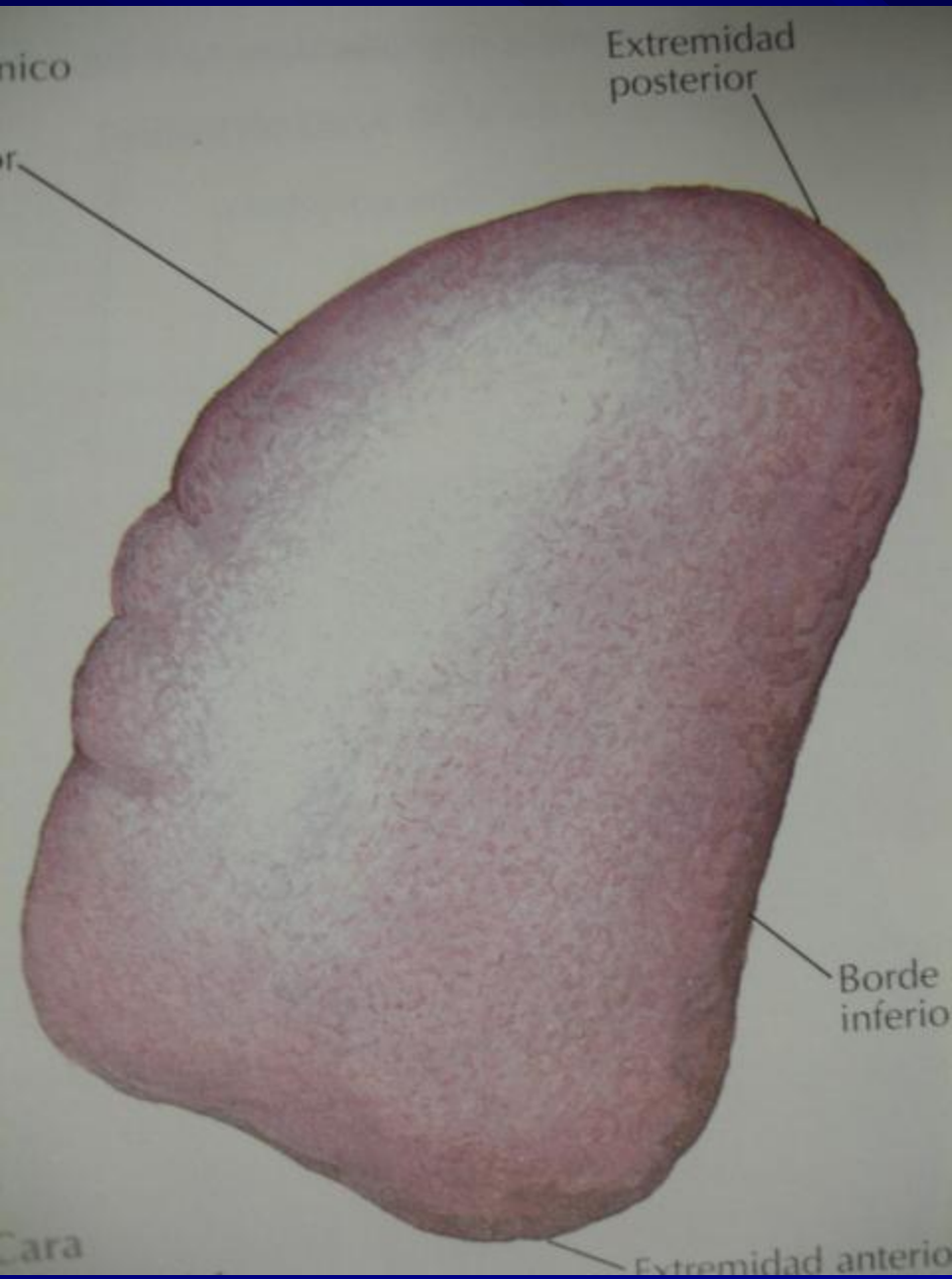


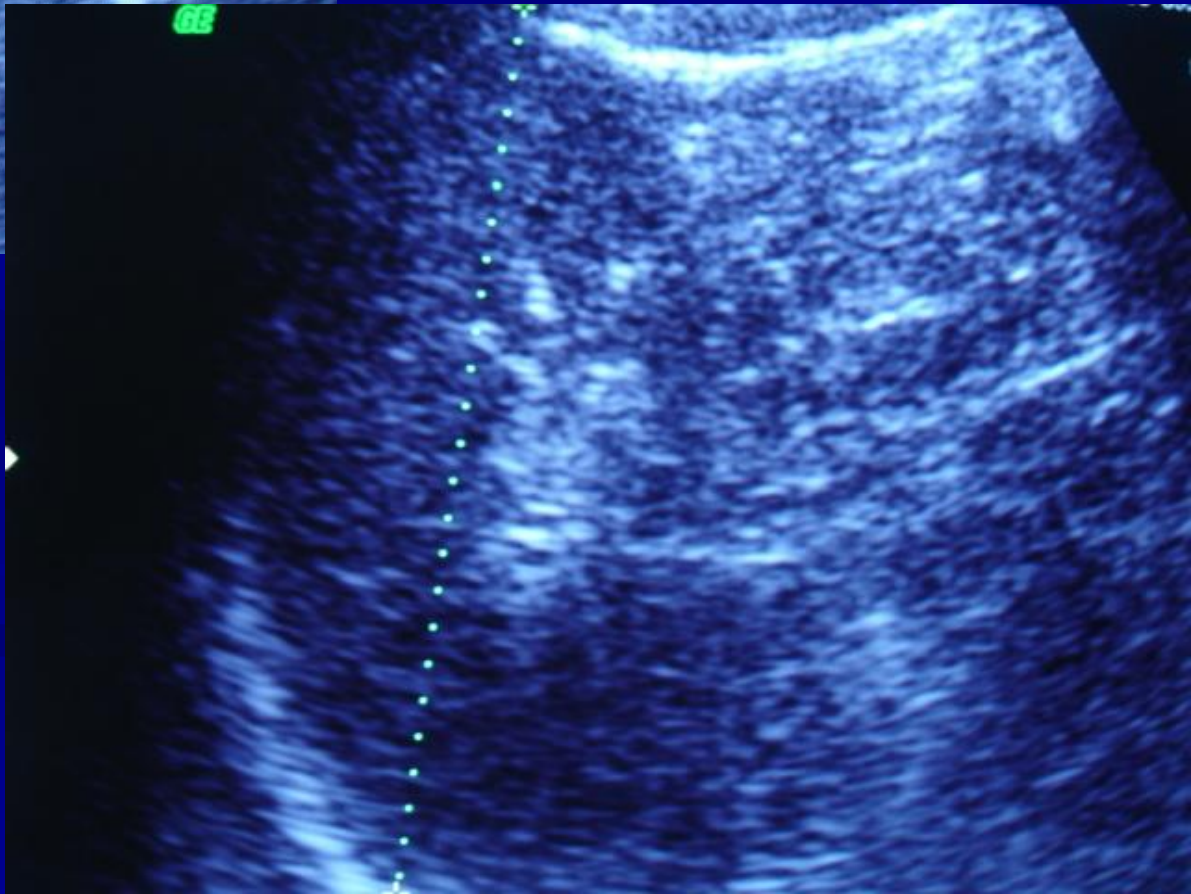
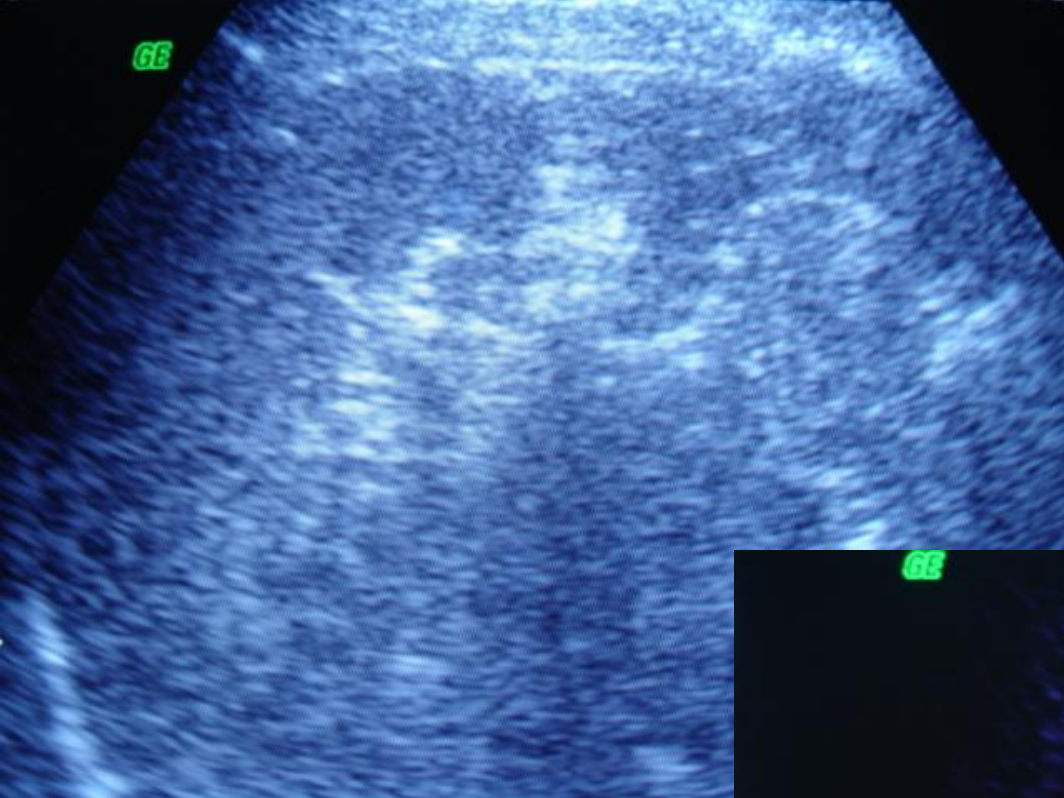




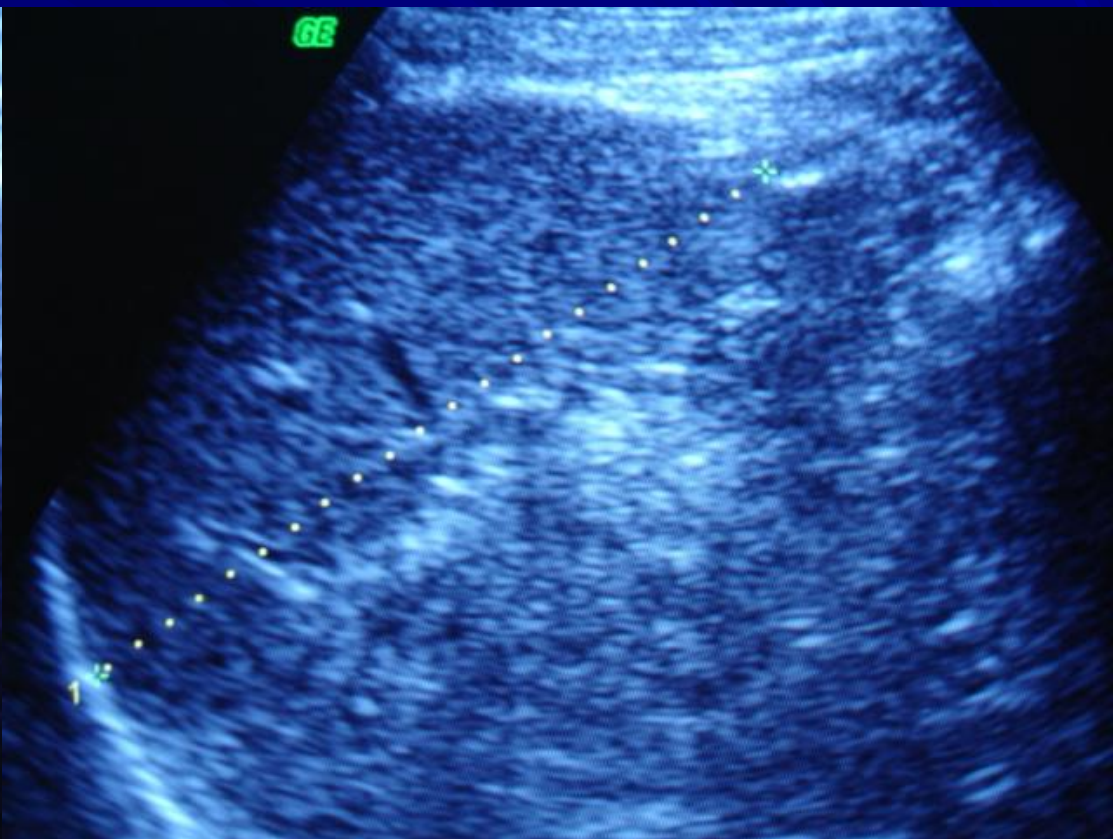
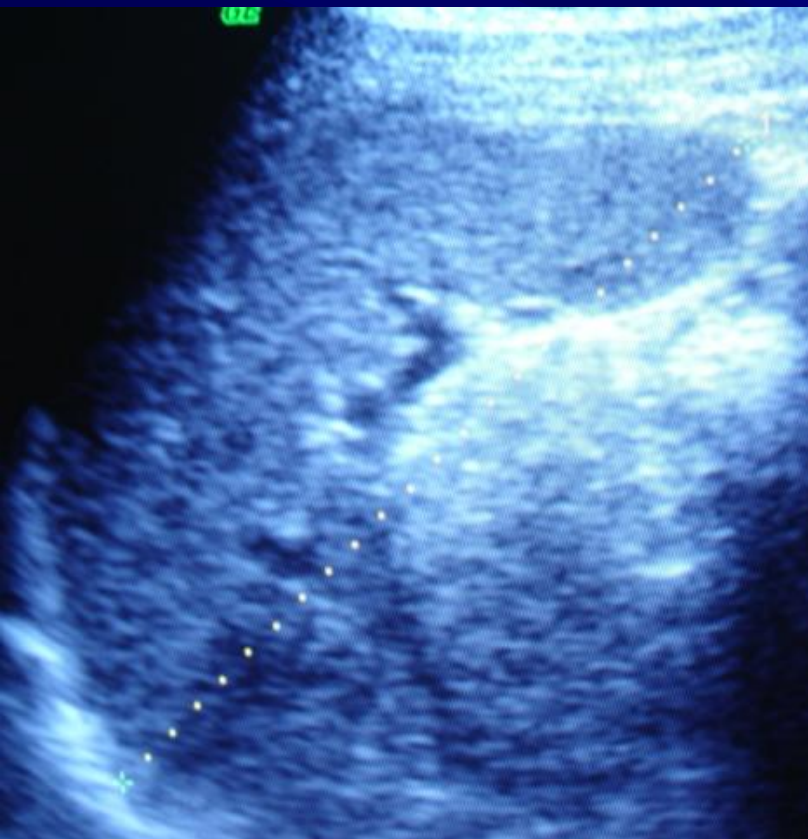


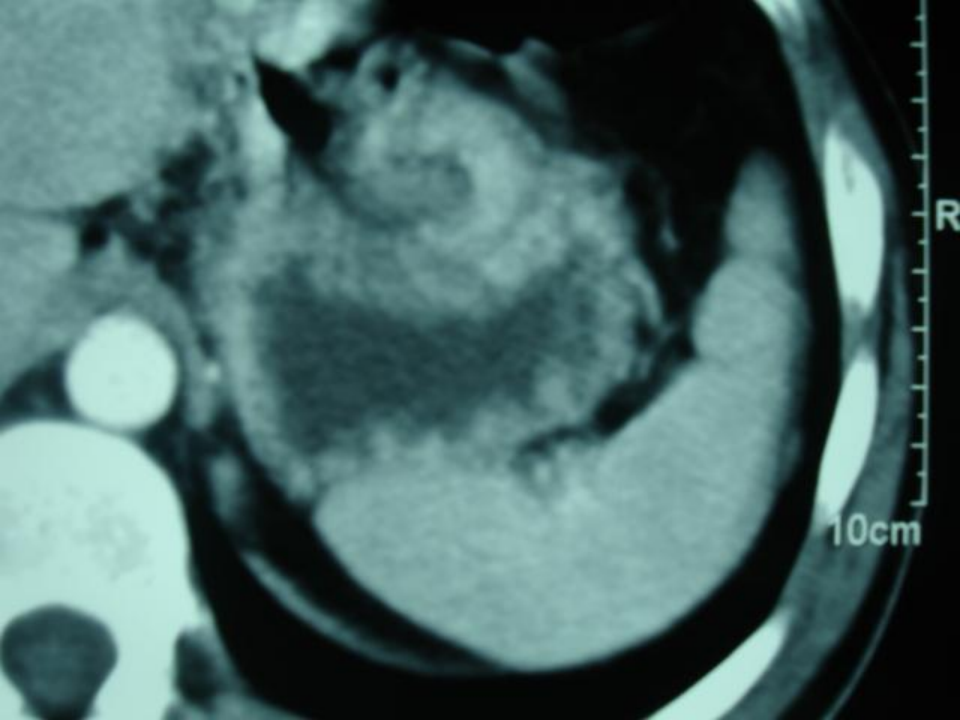
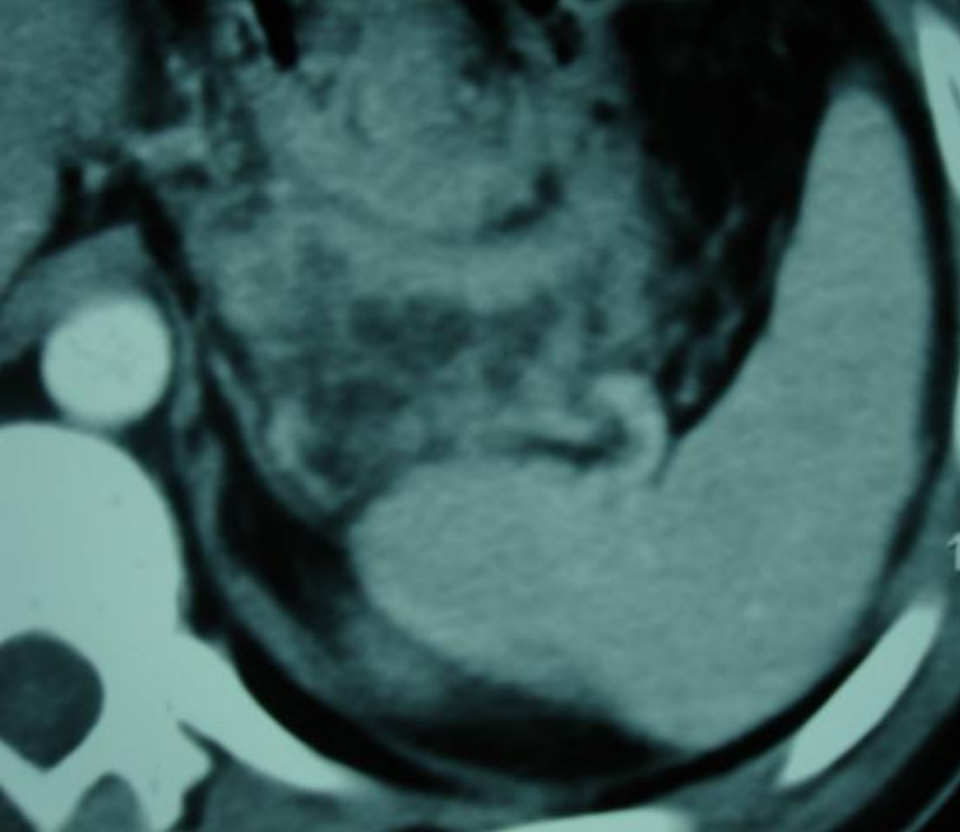




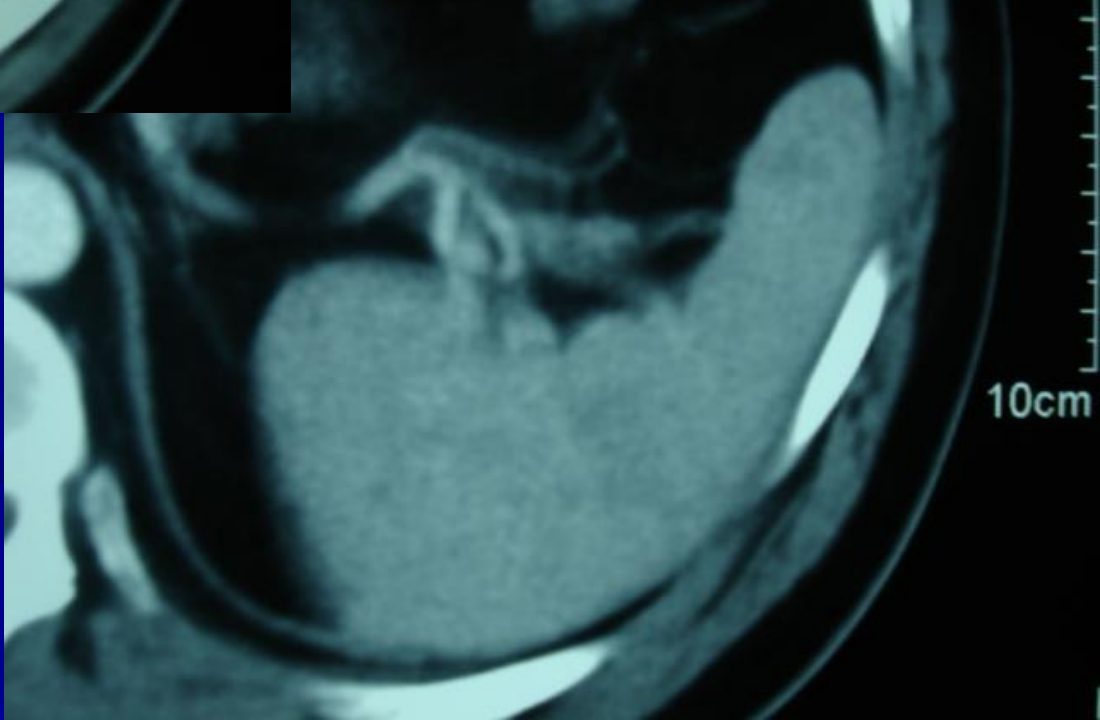


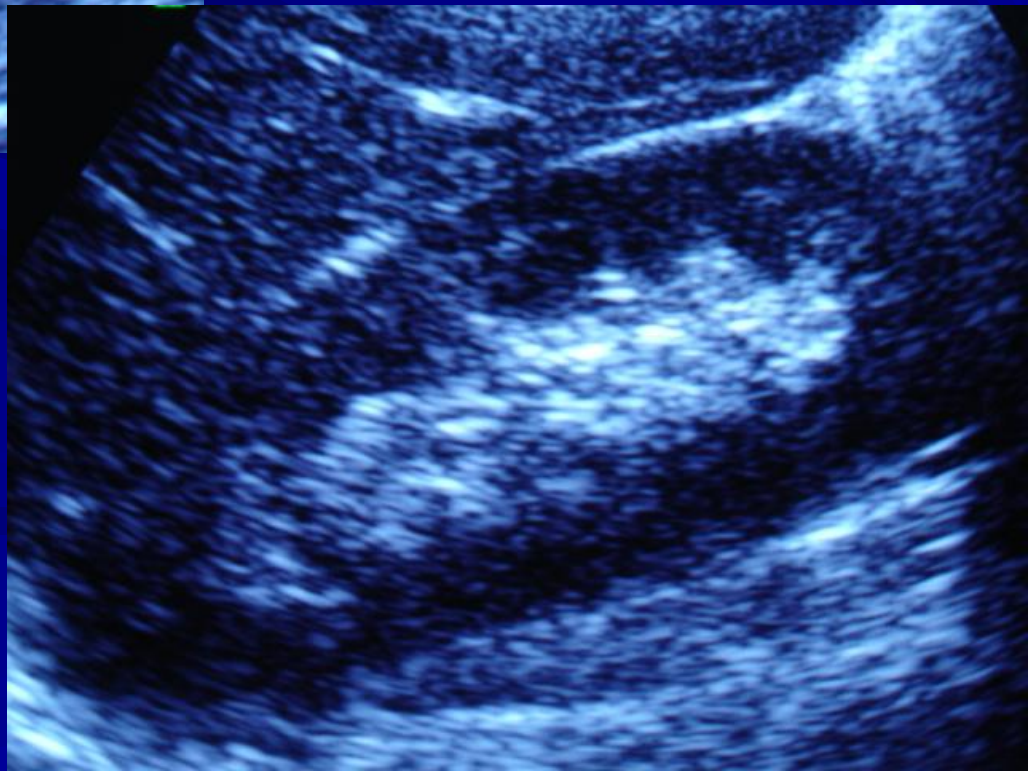
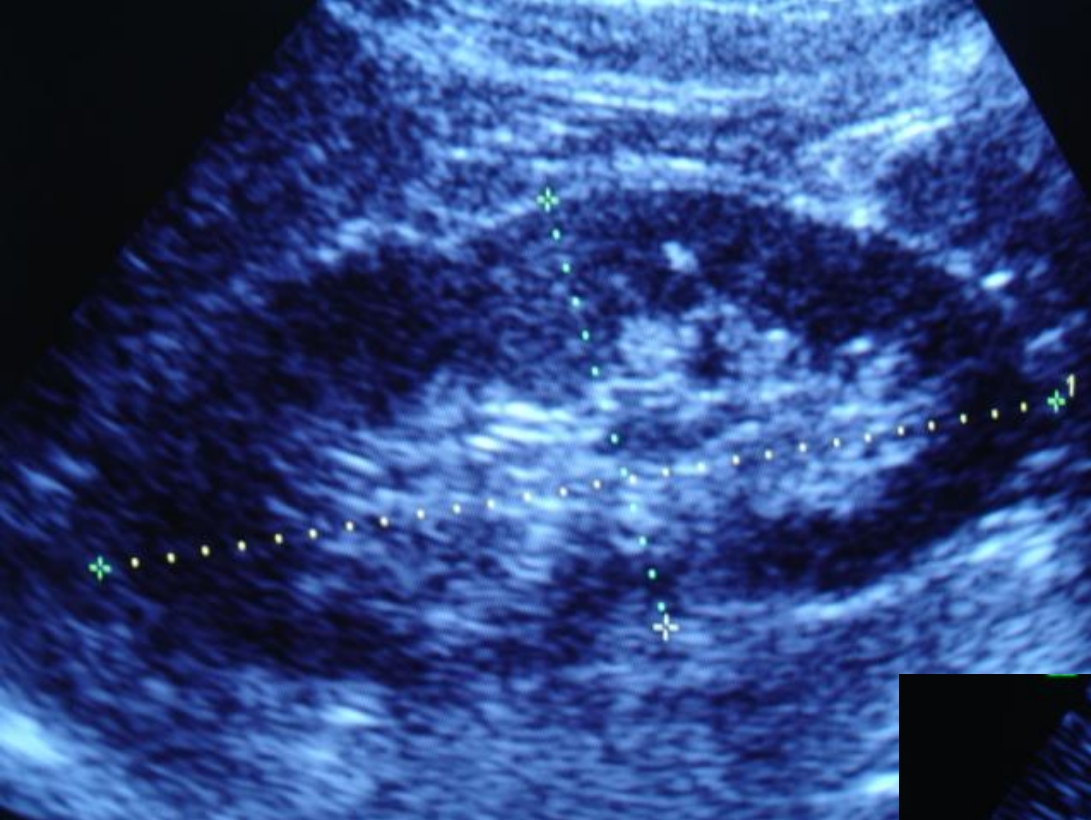


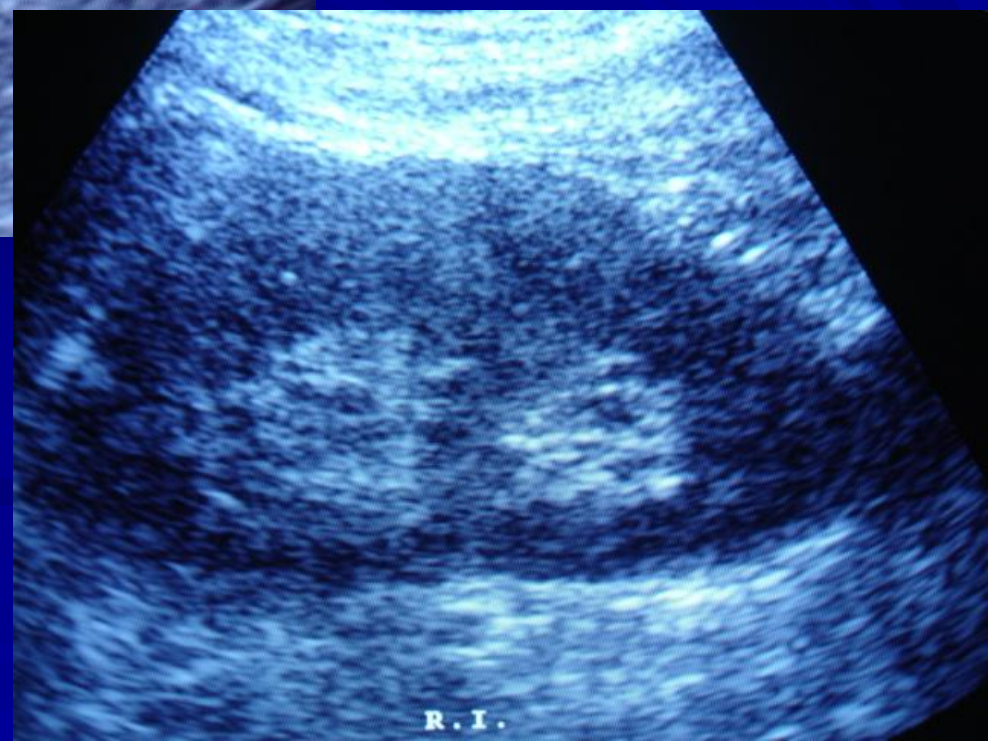
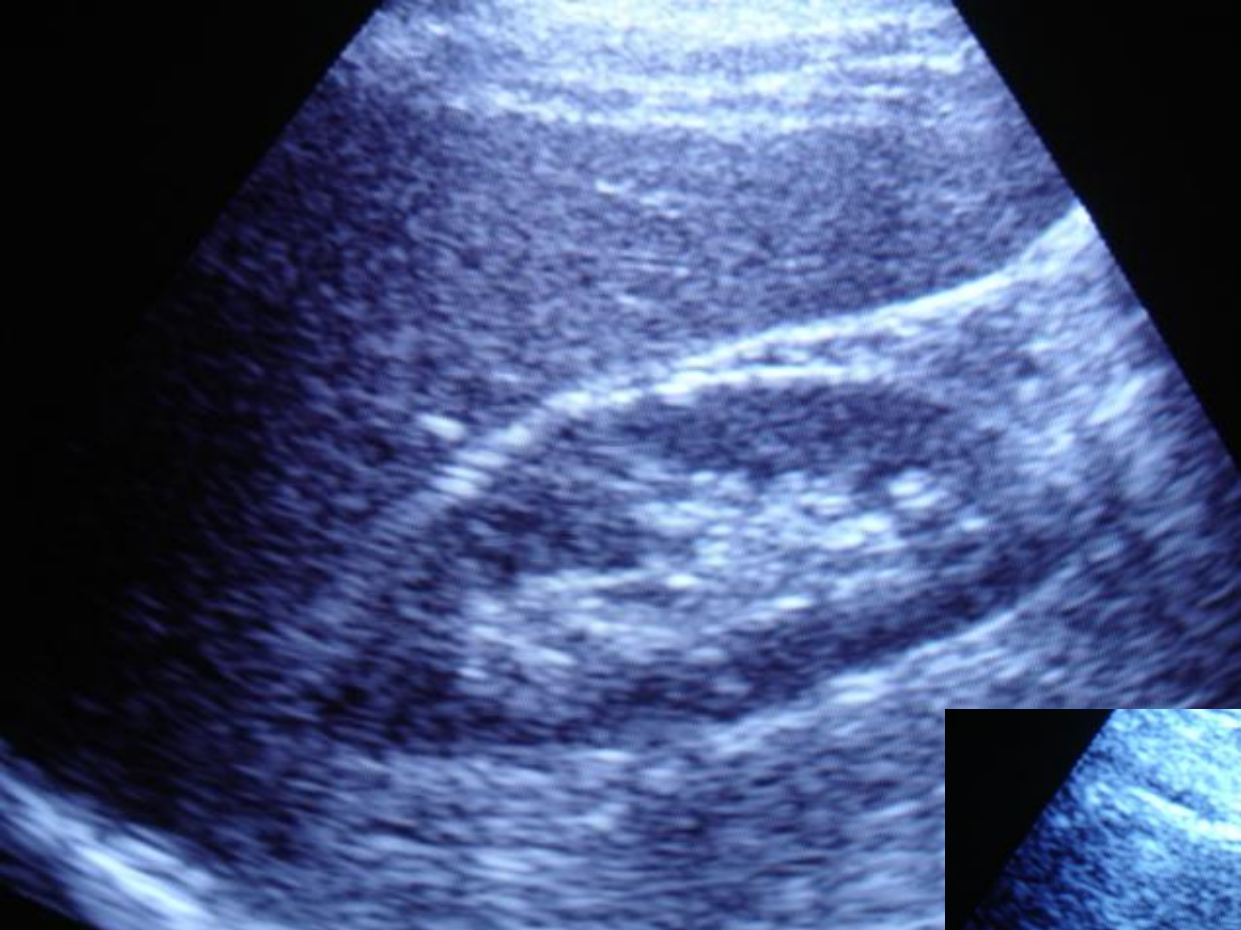




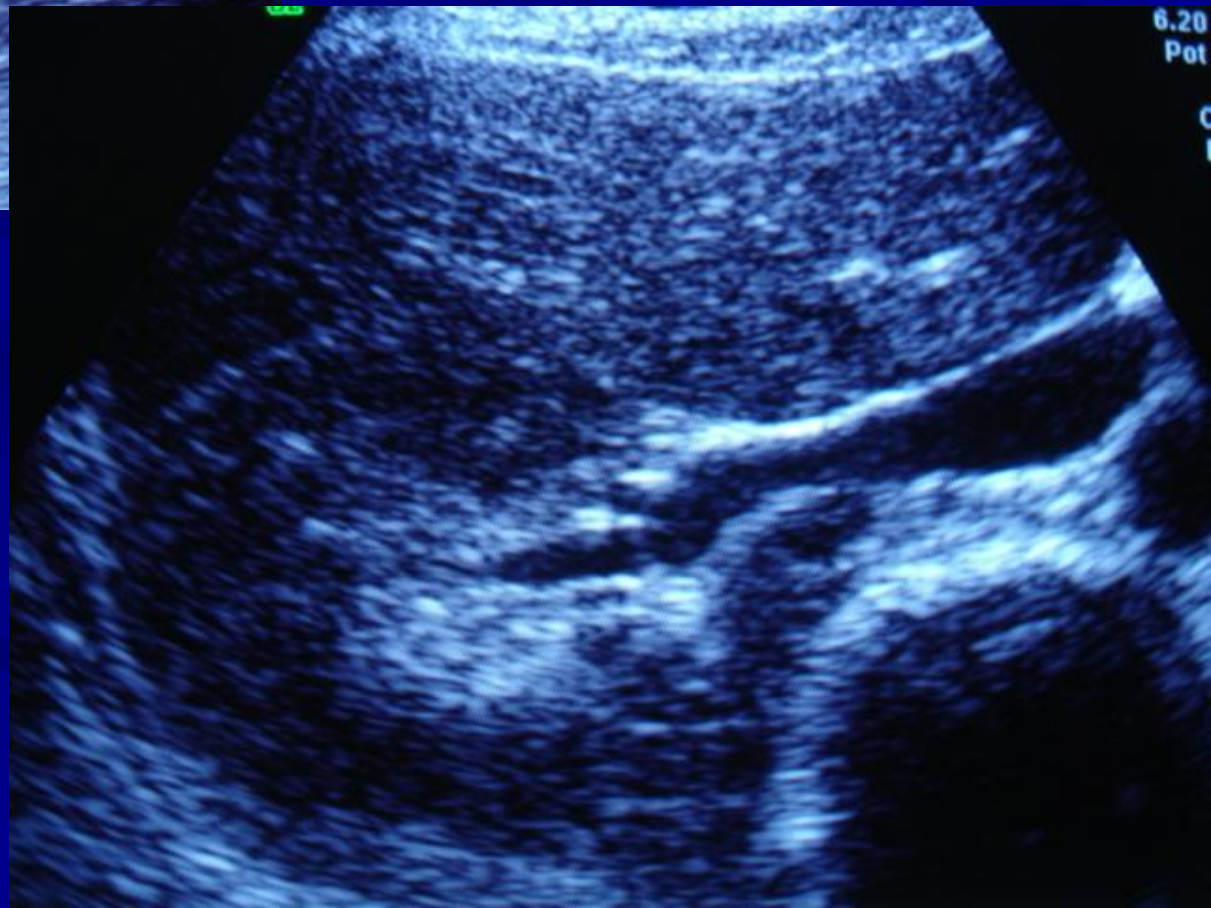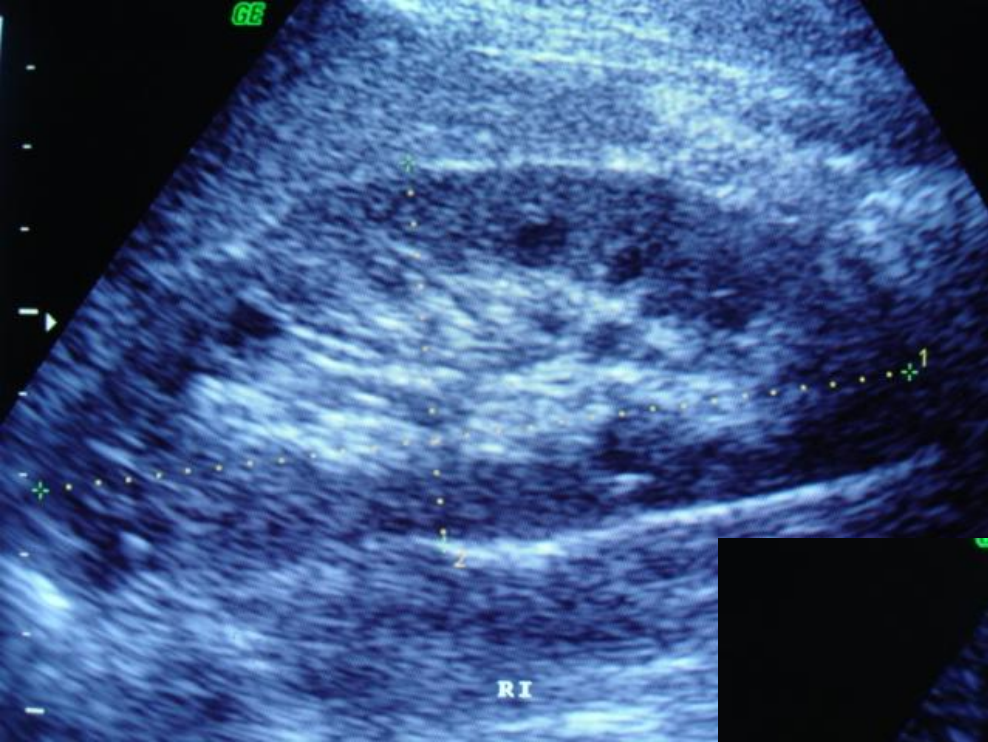**BAZO**

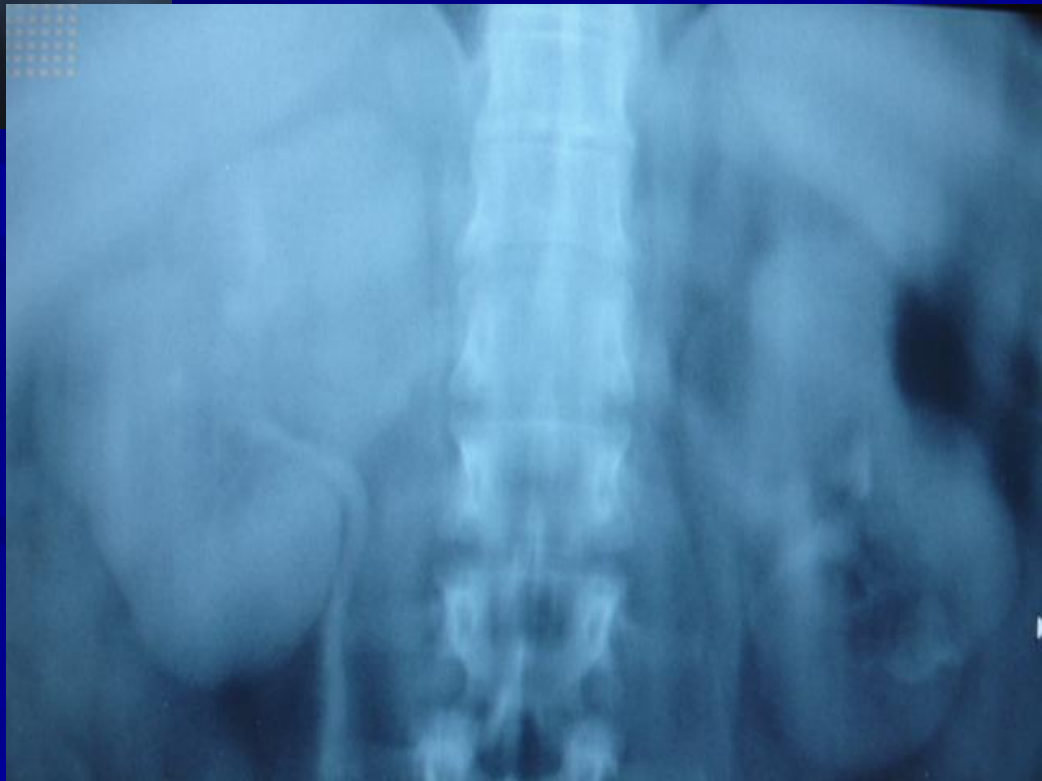
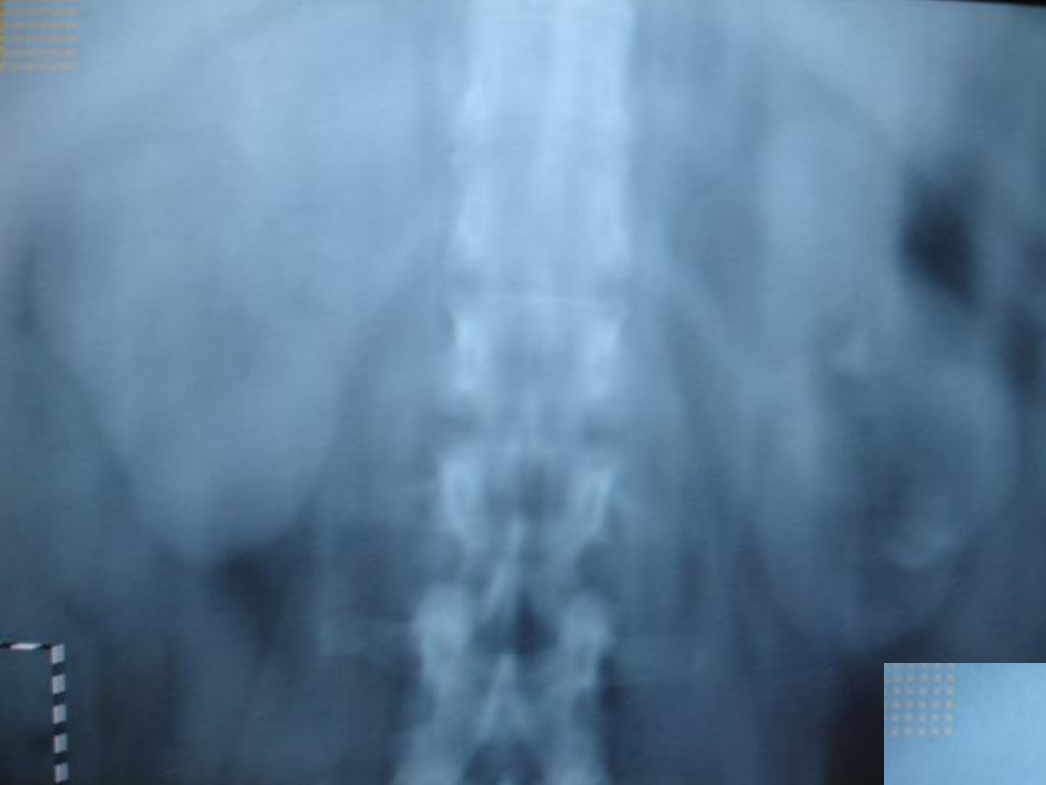




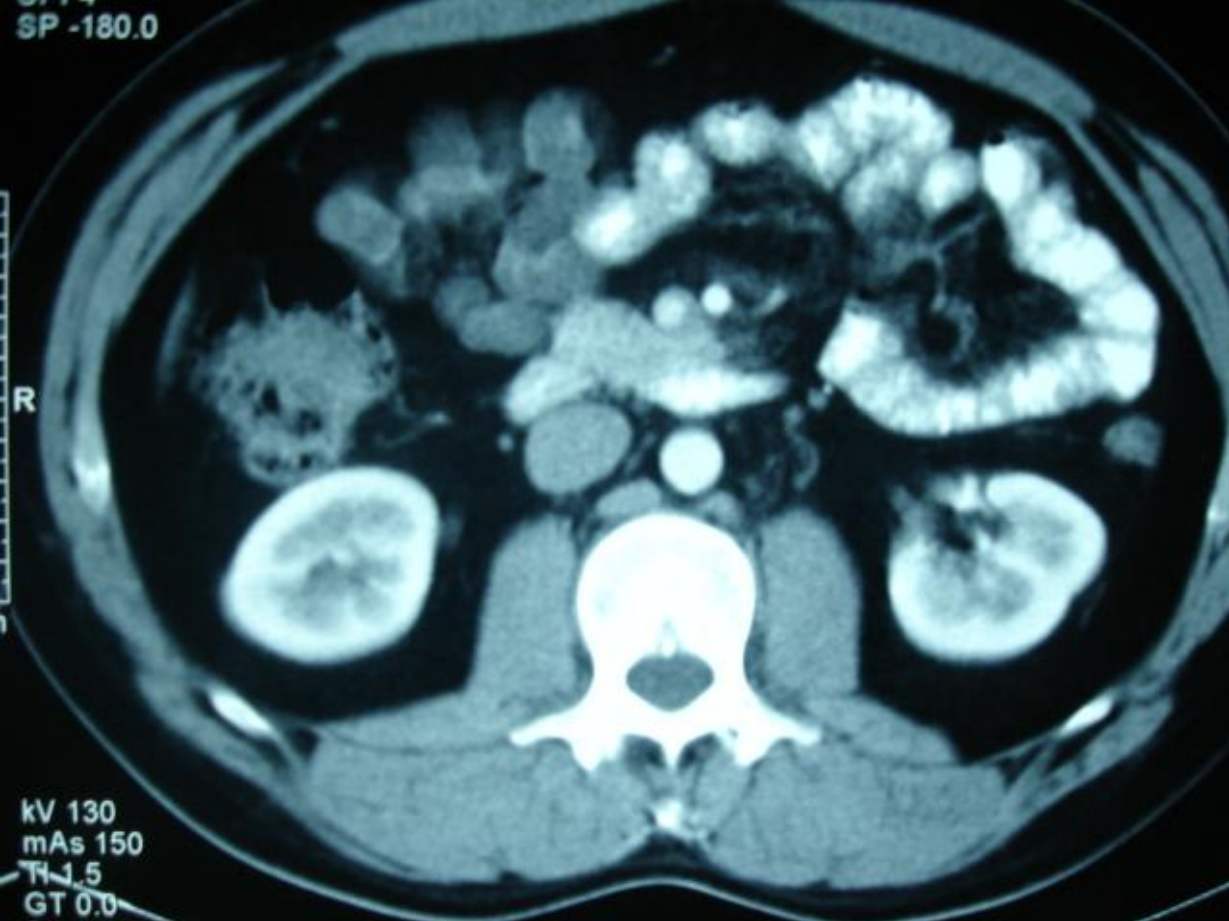R.I.

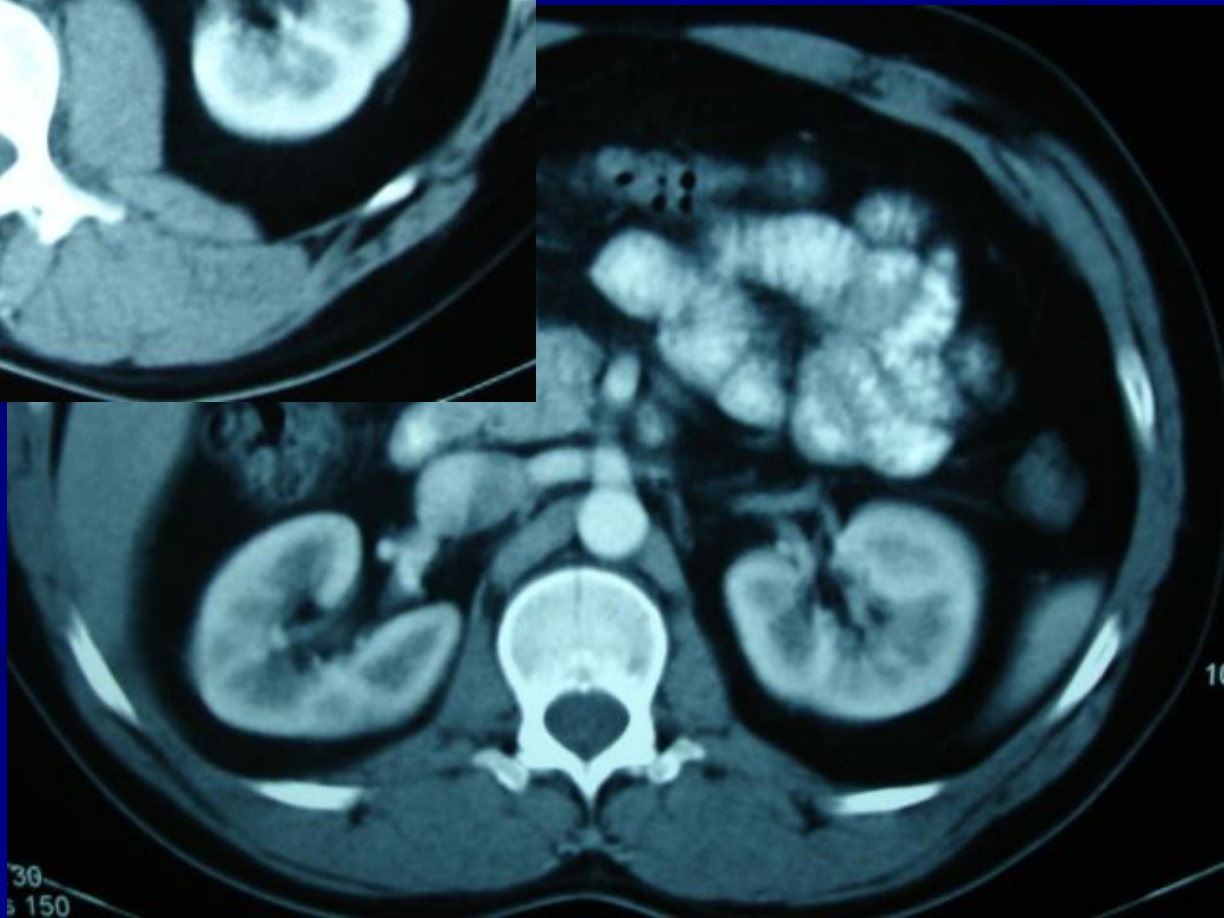



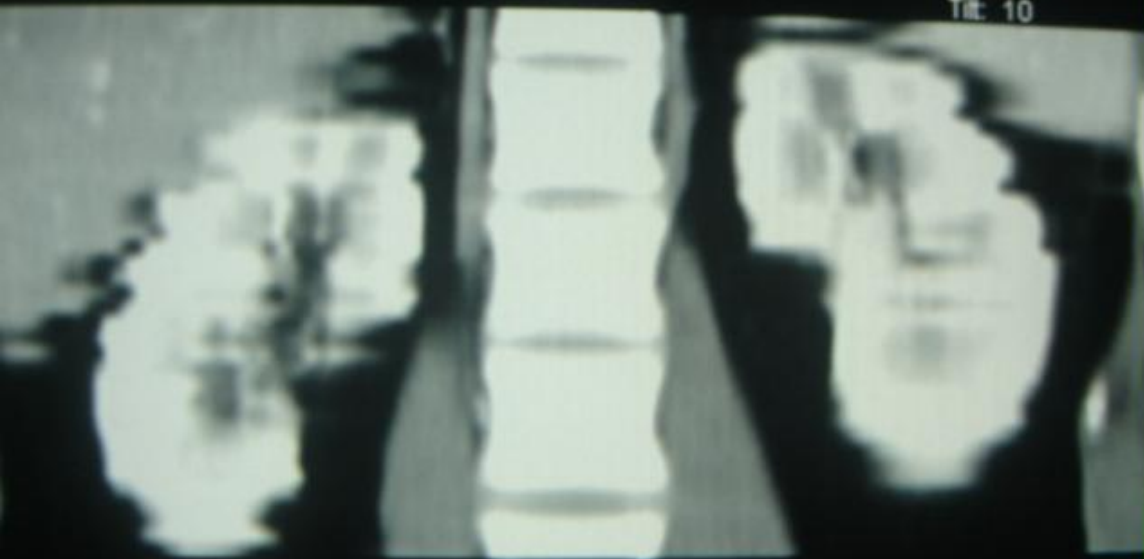# TOMOGRAFIA LIENAL RENAL



# RIÑONES



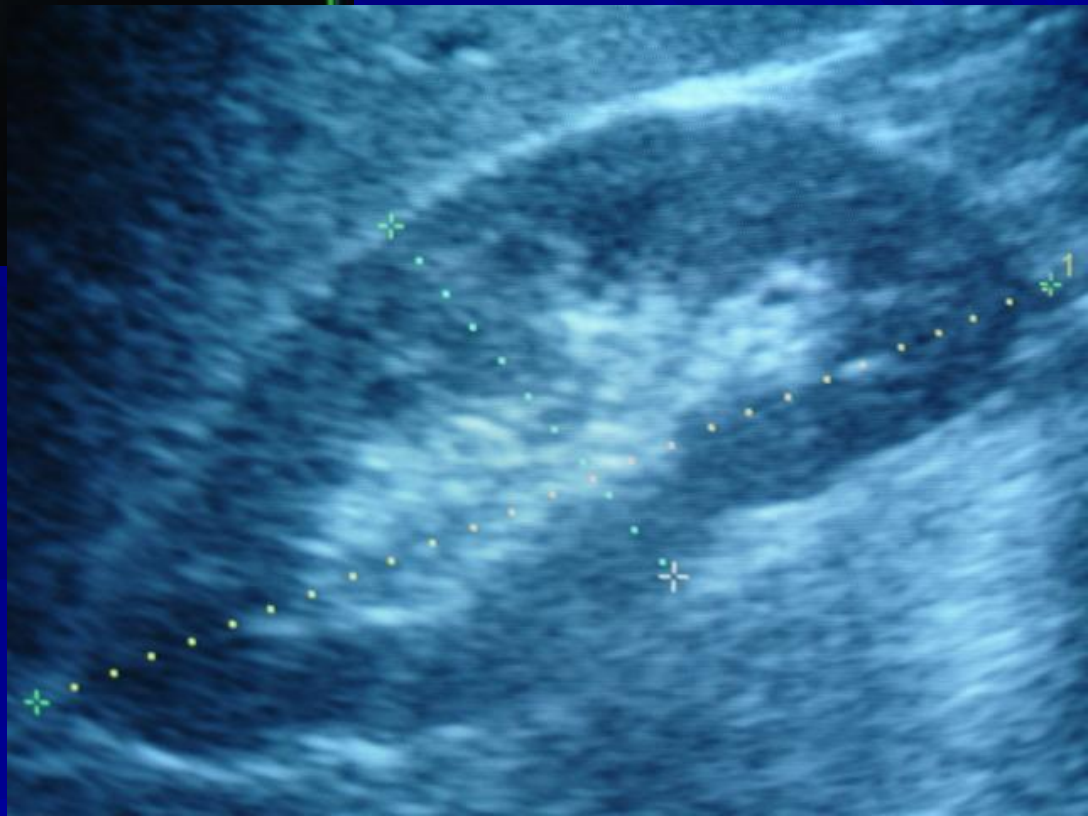
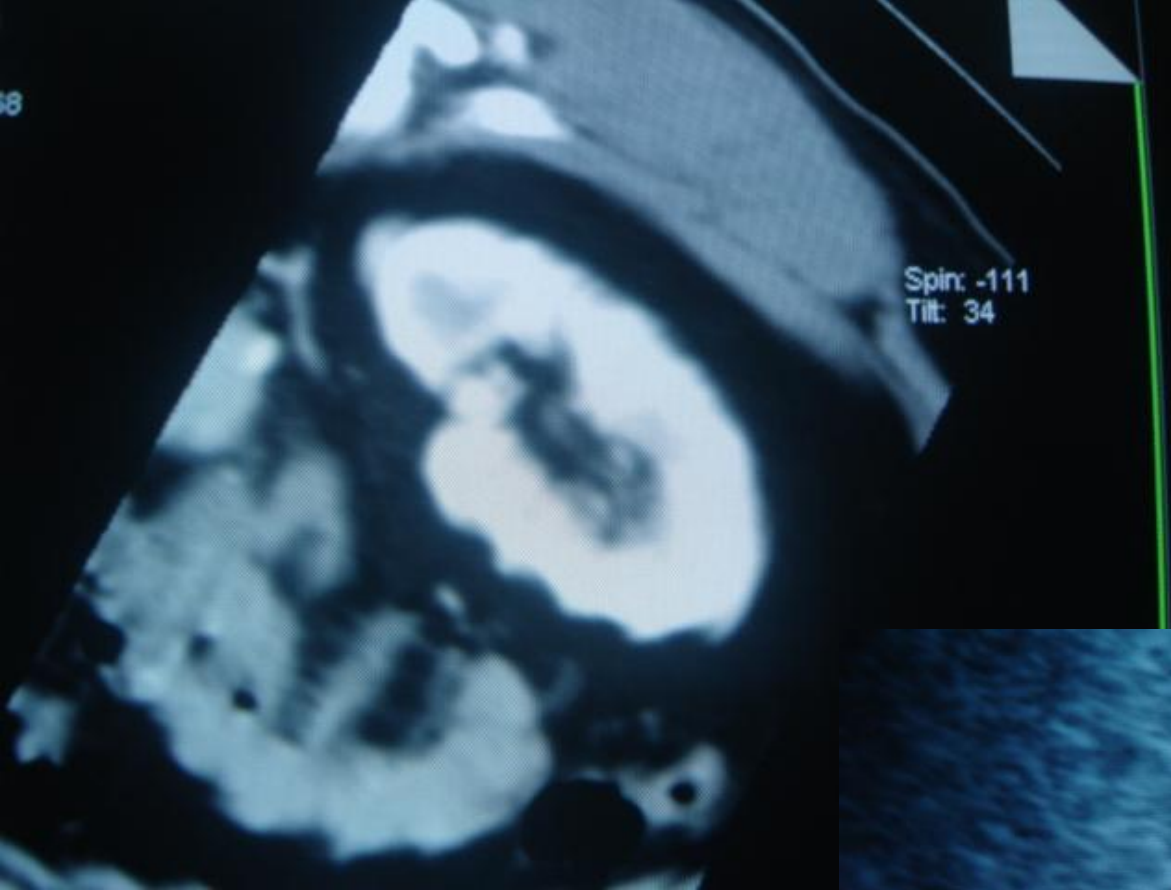Spin: -9  
Tilt: 10

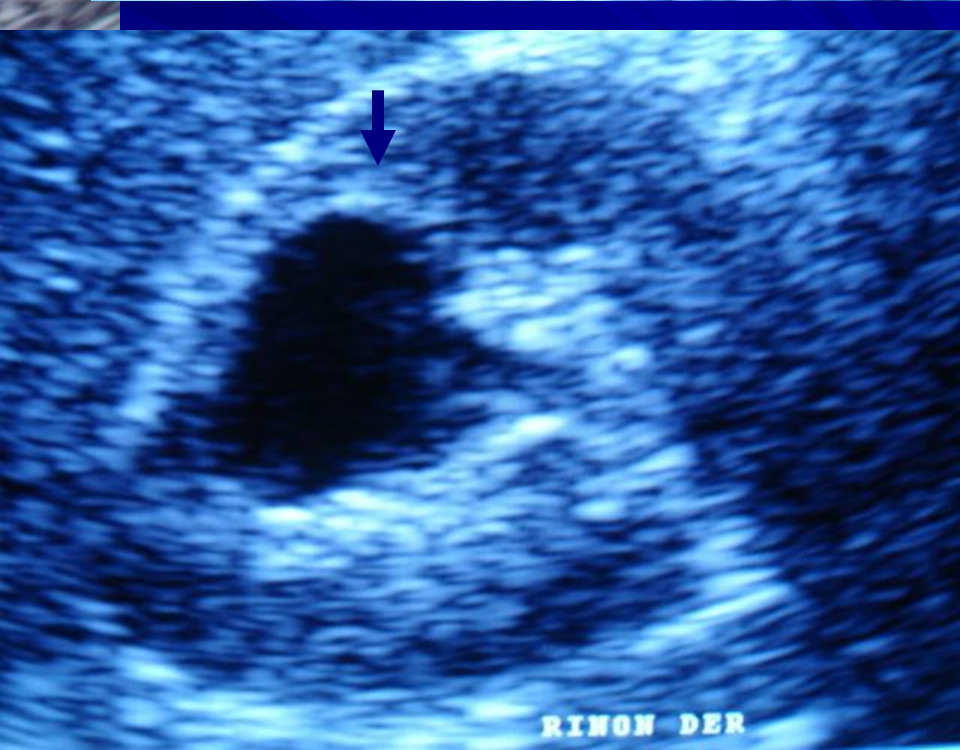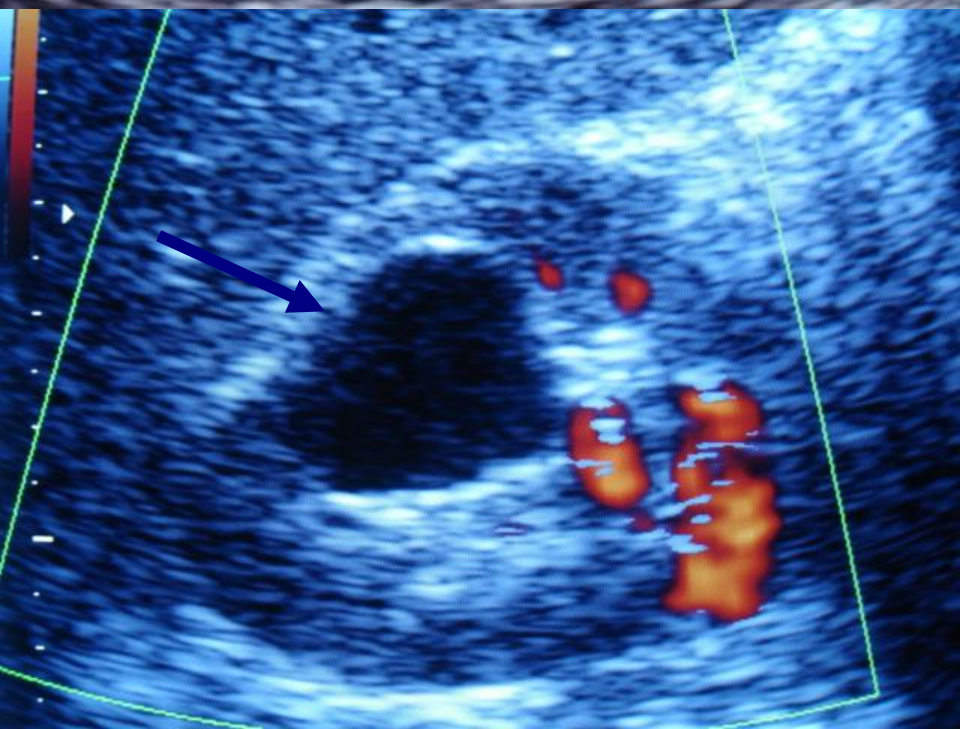
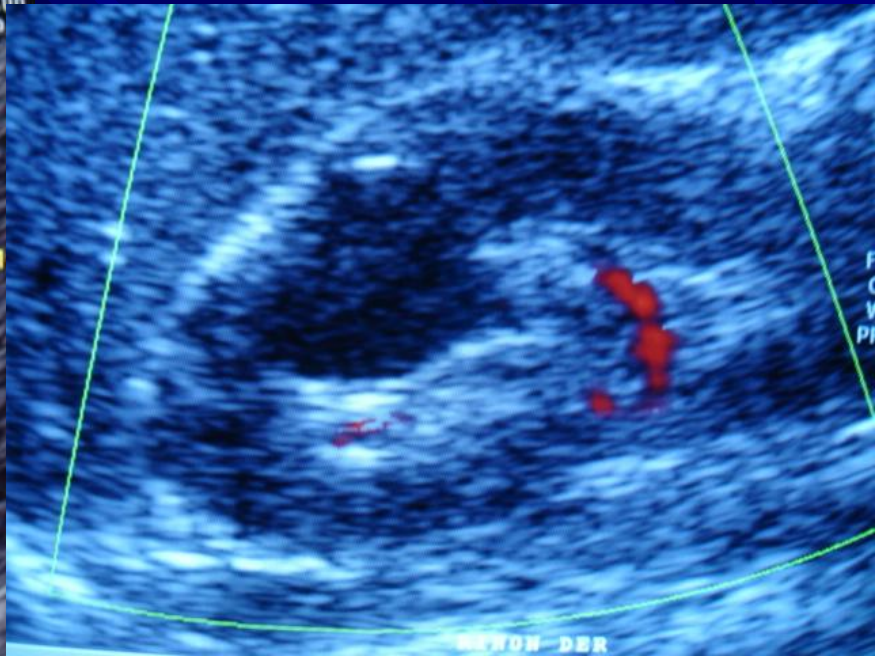
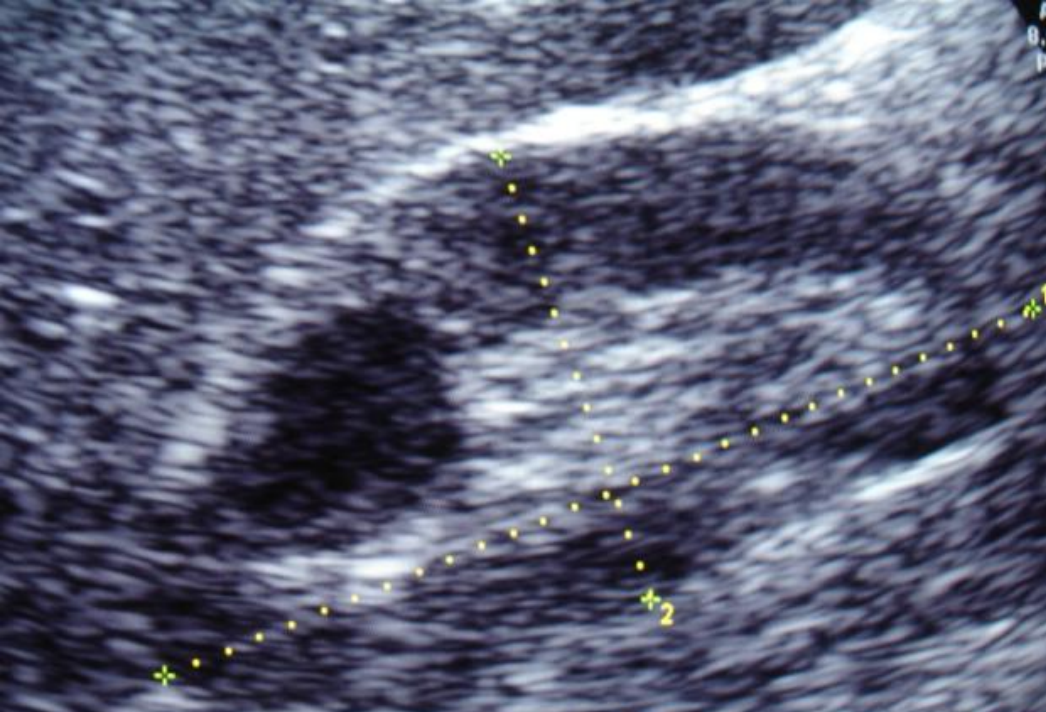


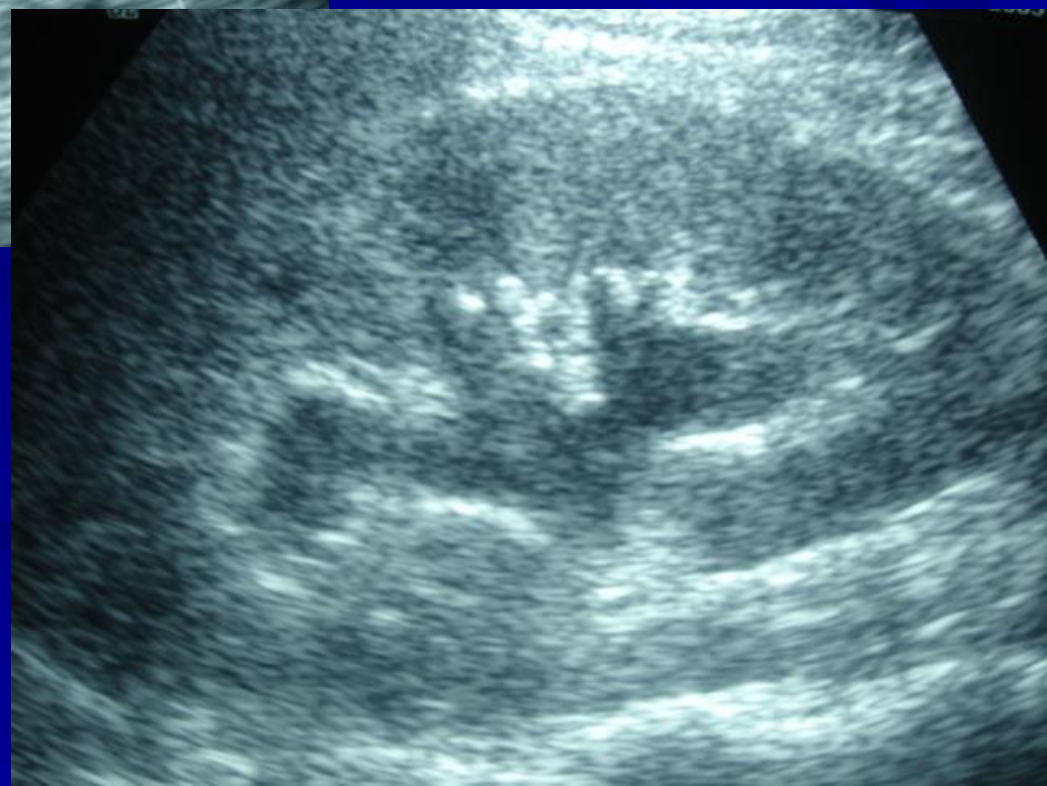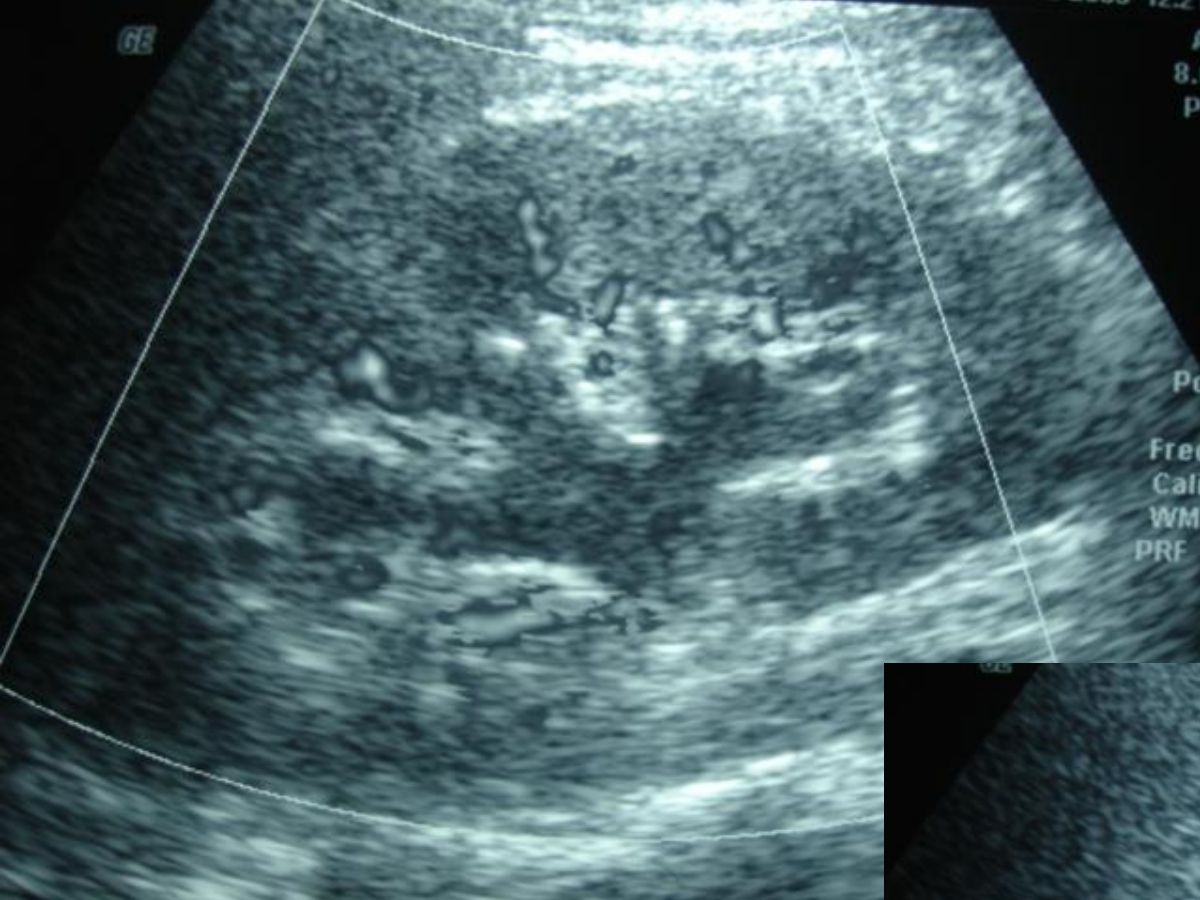Spin: -3  
Tilt: 9

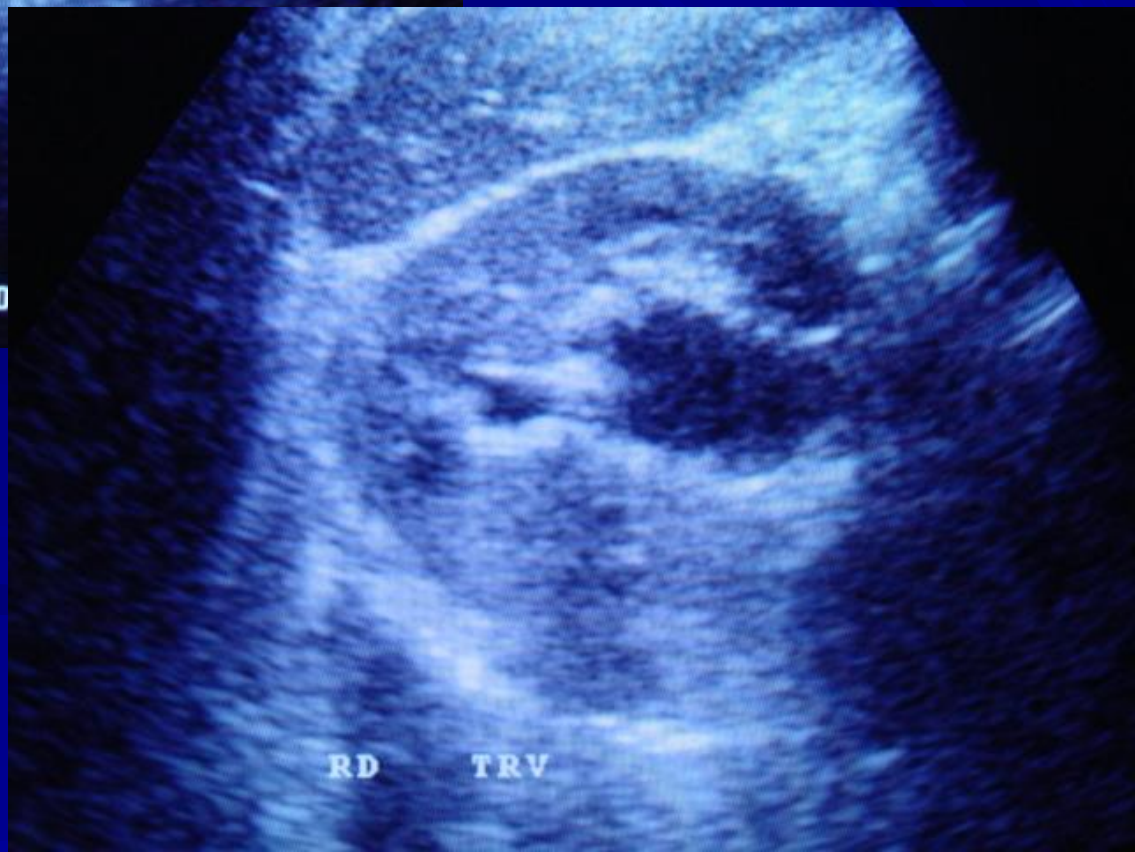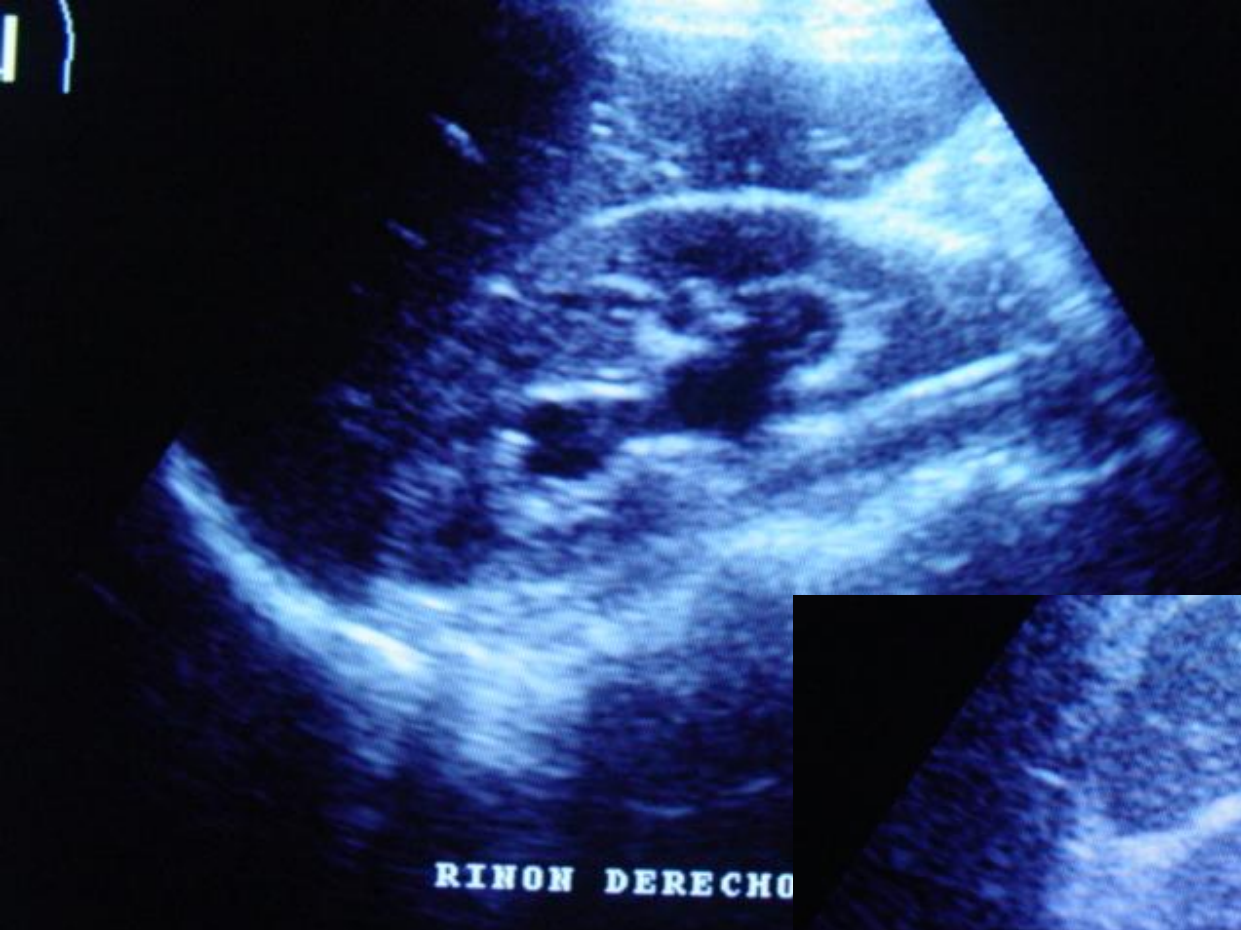











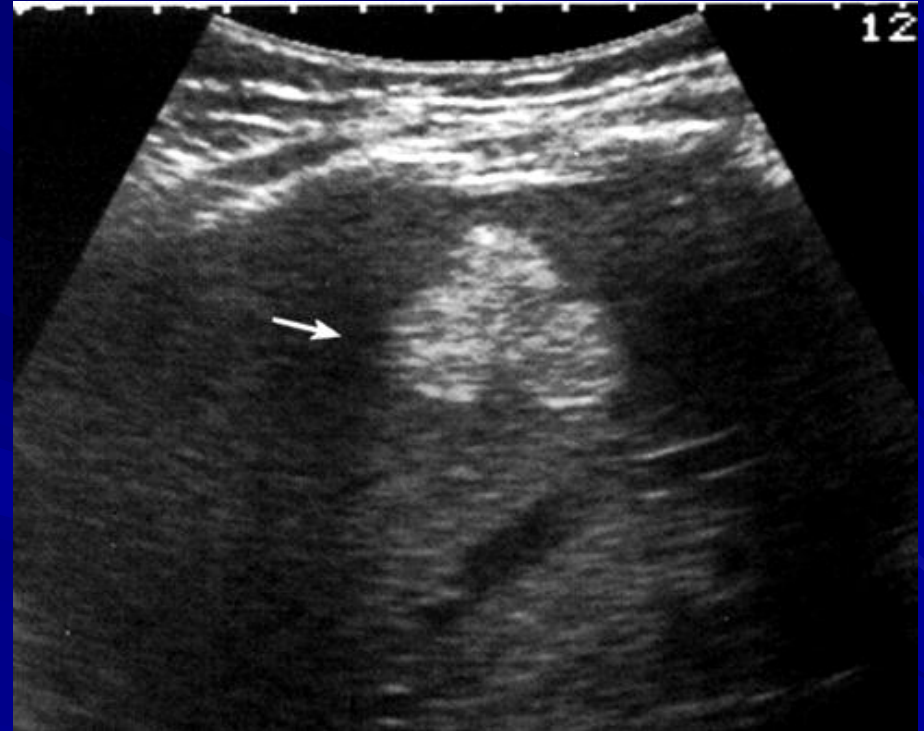
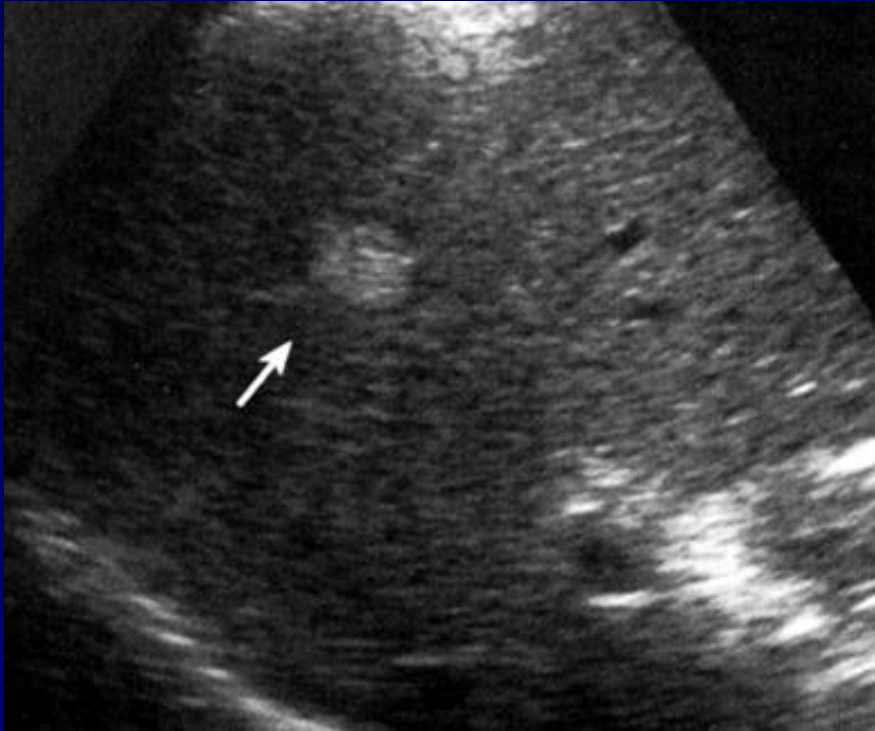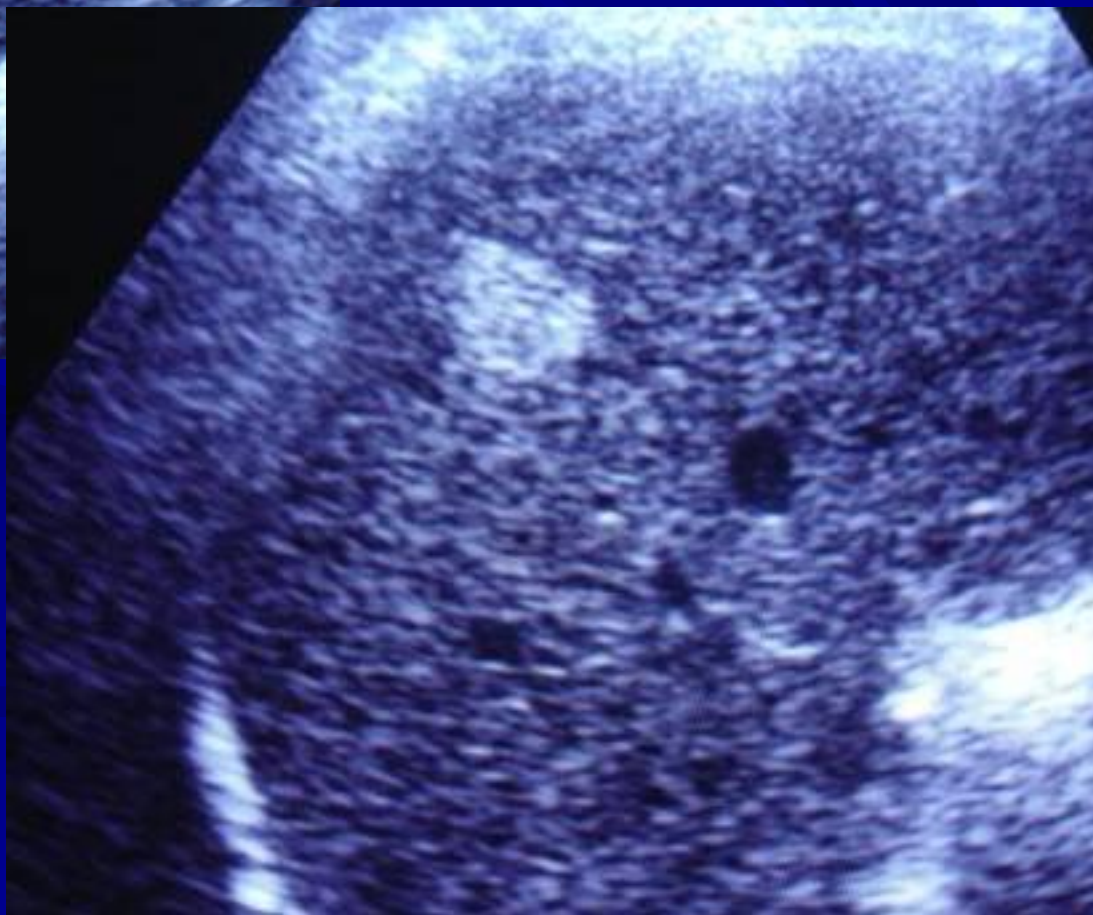
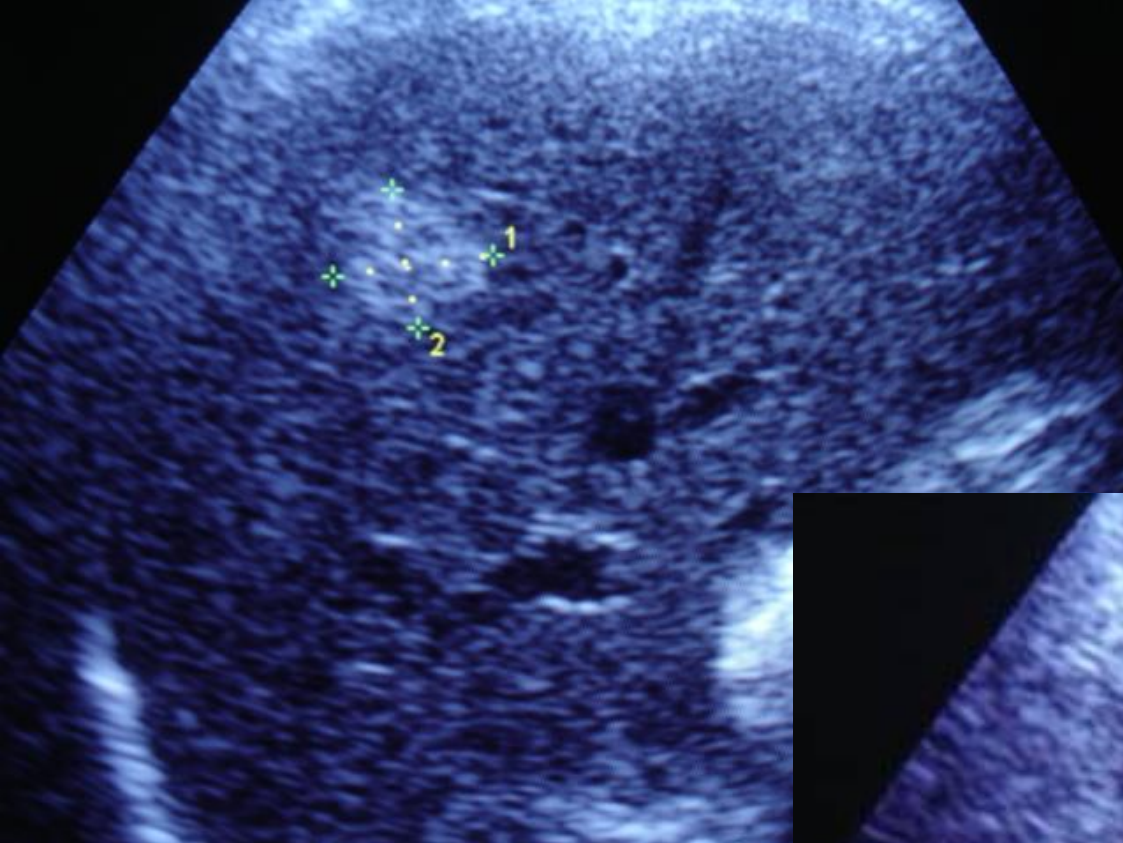
**PADECIMIENTOS  
DE  
HIGADO Y VIAS BILIARES**

# HEMANGIOMA HEPATICO

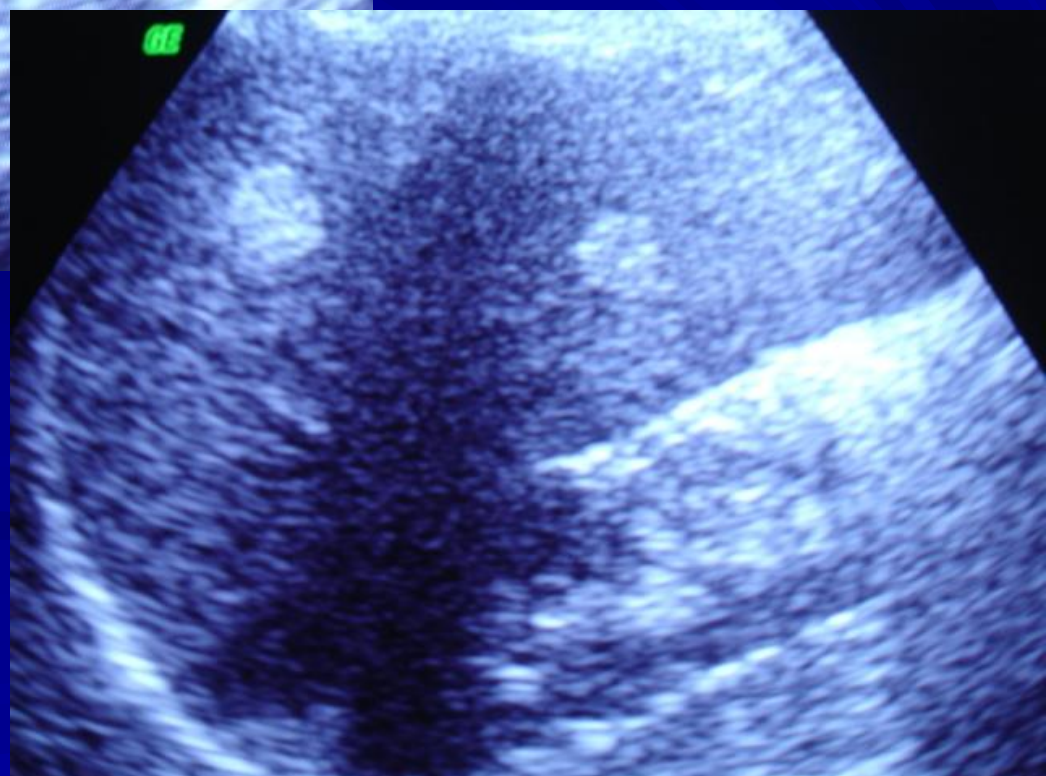
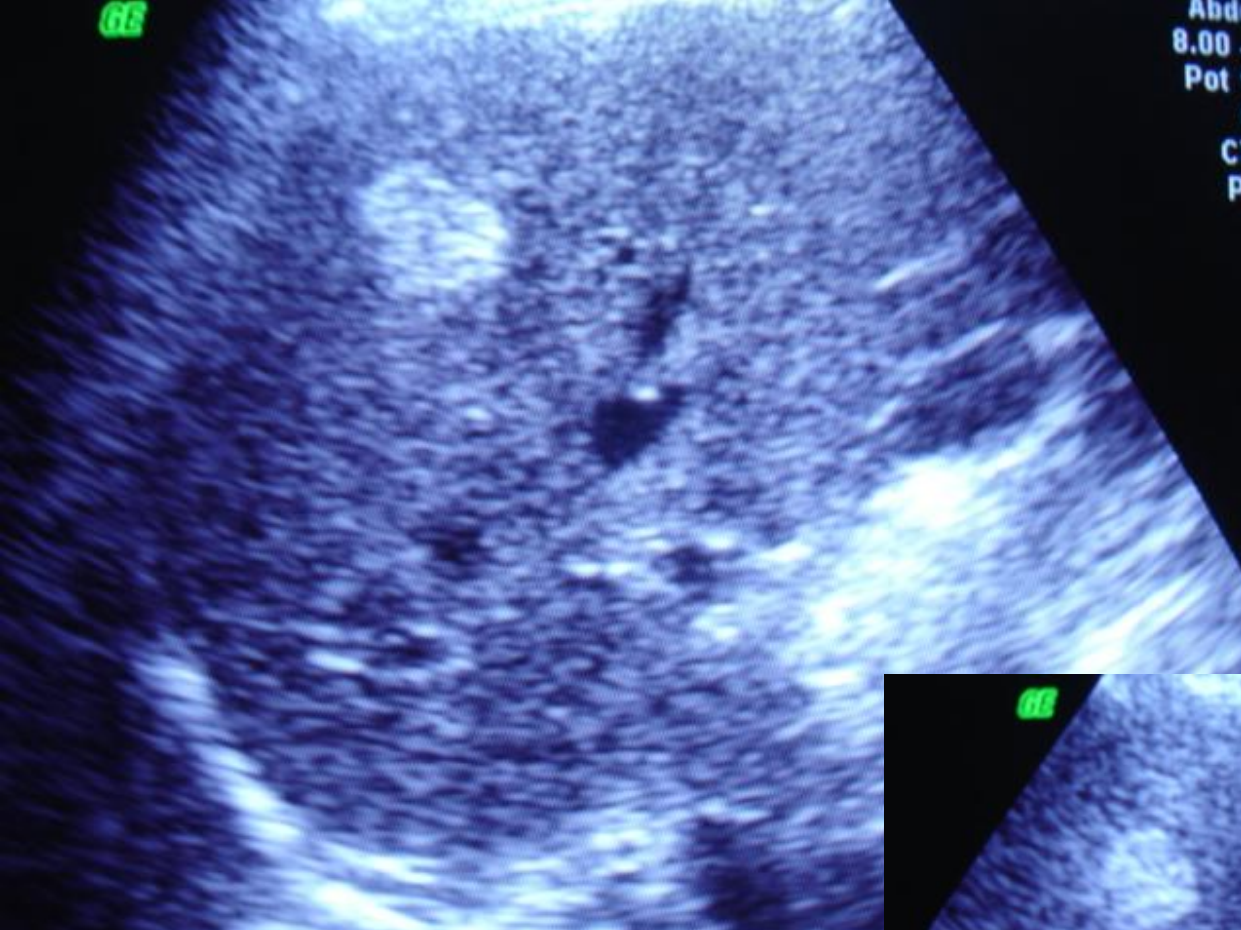
- TUMOR BENIGNO MAS FRECUENTE
- MAS COMUN EN LAS MUJERES
- SON ESTRUCTURAS VASCULARES RECUBIERTAS DE ENDOTELIO SEPARADAS POR ESTROMA FIBROSO
- UNICOS
- PERIFERICOS(SUBCAPSULAR)
- MIDEN DE 1. 5-20 cm
- HIPERECOICOS

# HEMANGIOMA HEPATICO

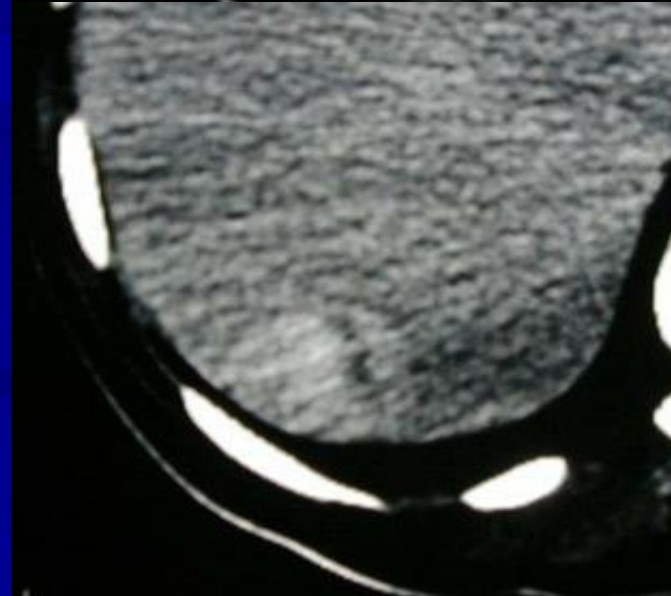
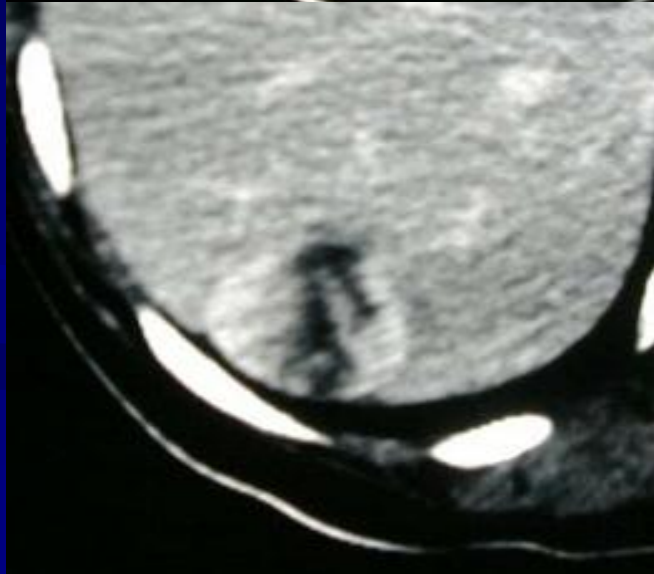
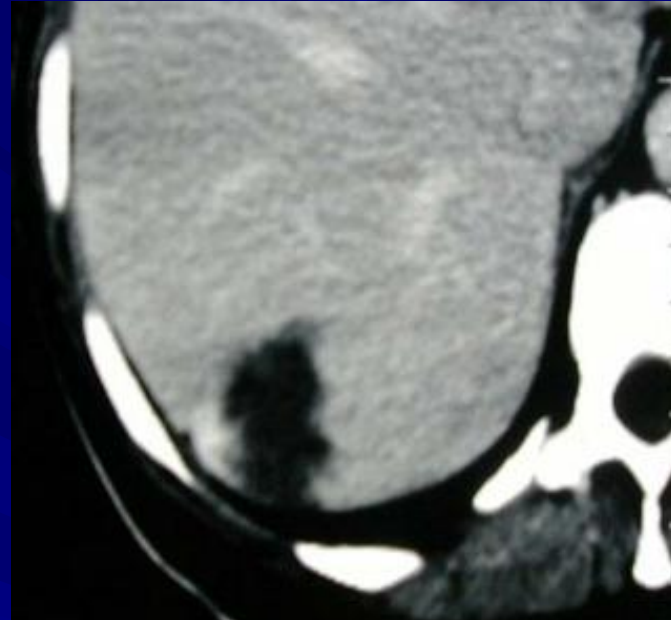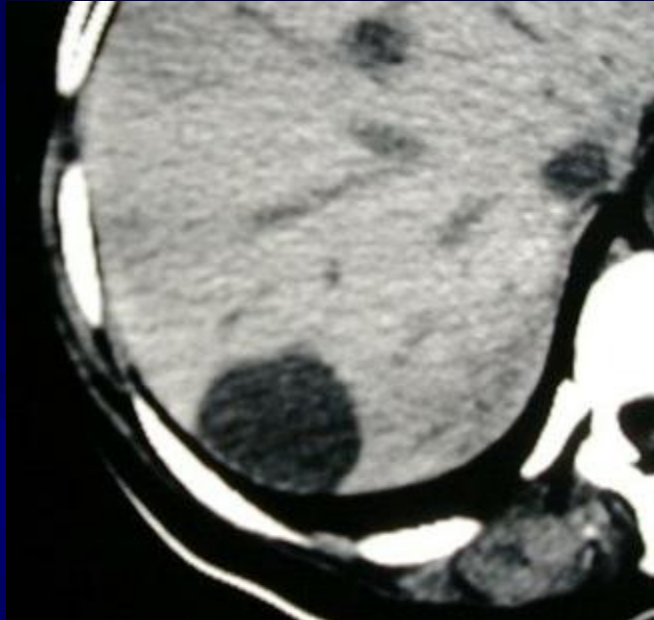








# HEMANGIOMA HEPATICO

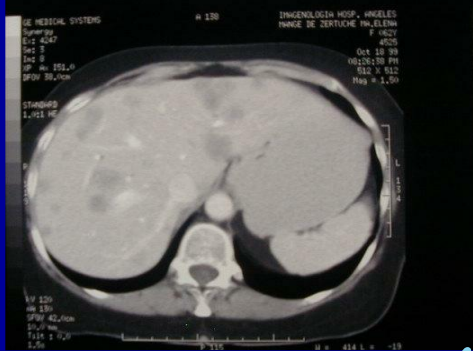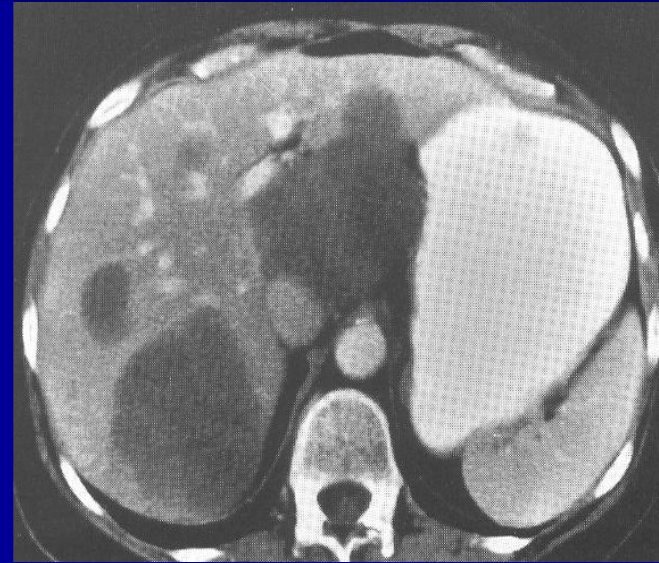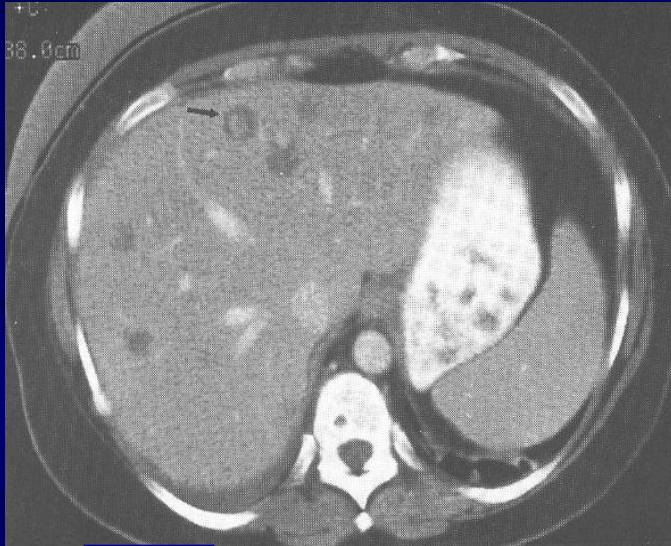


# **METASTASIS**

**GENERALMENTE PROCEDEN DE:**

- CA DE COLON**
- CA PANCREATICO**
- CA GASTRICO**
- CA DE MAMA Y PULMON**
- TUMORES PRODUCTORES DE MUCINA**

# METASTASIS



**SUELEN SER MÚLTIPLES  
PUEDEN SER HIPER O HIPOECOICAS**

# ADENOMA HEPATICO

TUMORES EPITELIALES BENIGNOS  
RELACION CON ANTICONSEPTIVOS  
CON ENFERMEDADES METABOLICAS



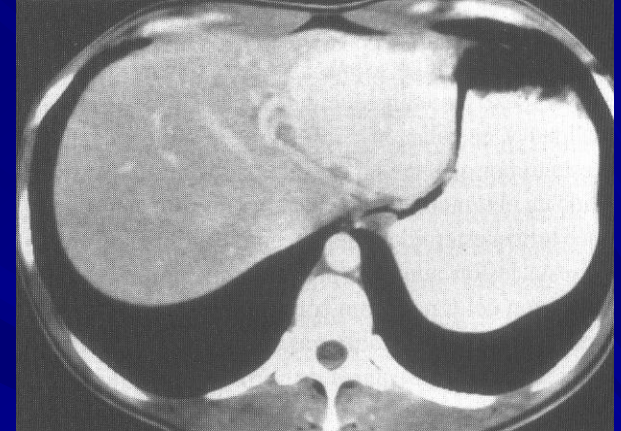
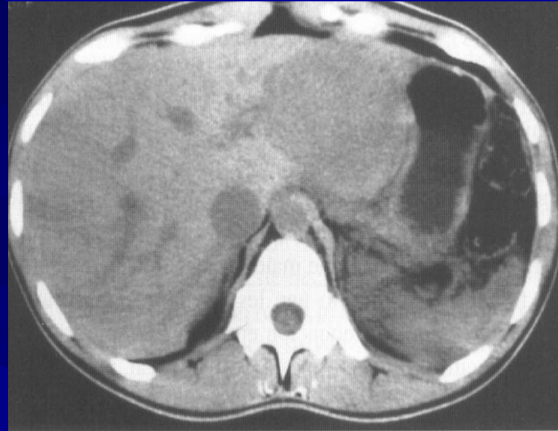
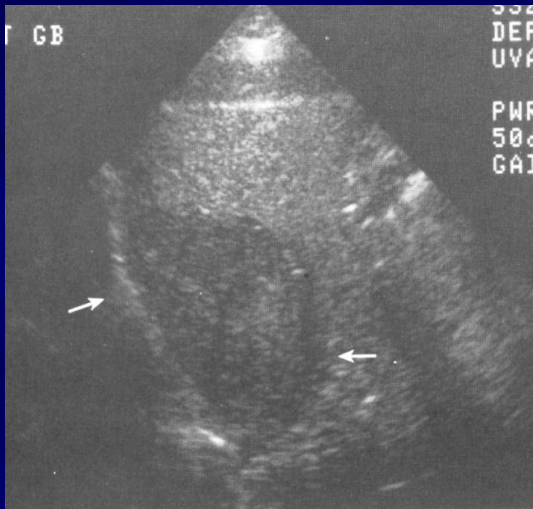
GLUCOGENOLISIS



USO DE ESTEROIDES

GENERALMENTE ASINTOMATICOS

# ADENOMA HEPATICO

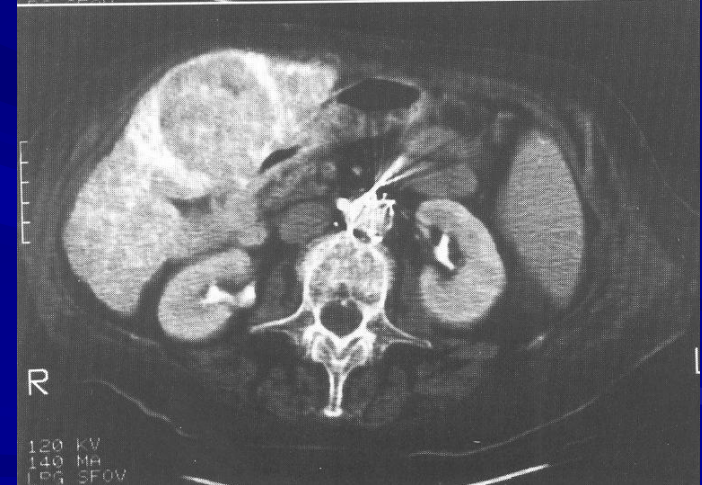
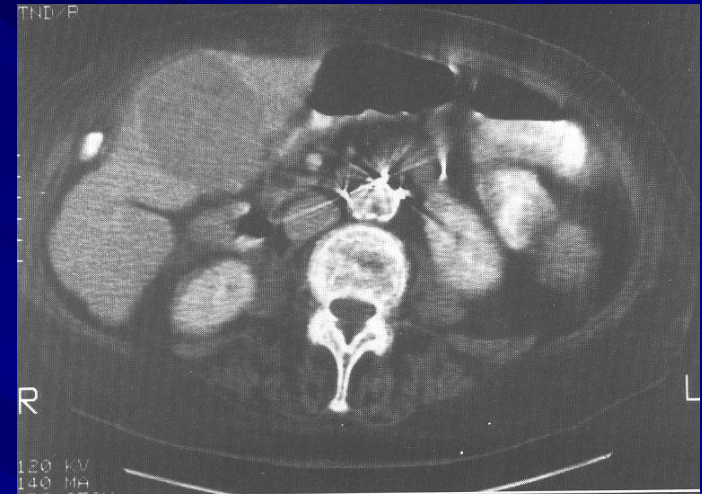
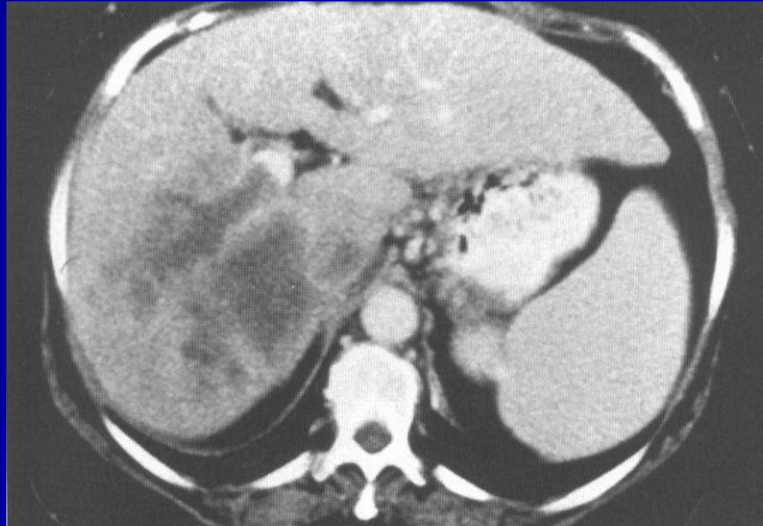
**PUEDE PRESENTAR ABDOMEN AGUDO**  
**HEMOPERITONEO**  
**PUEDE DEGENERAR EN CARCINOMA**  
**MASA UNICA DE 8-15 cm**  
**HIPERECOICOS**

# CARCINOMA HEPATOCELULAR

- FRECUENCIA ALTA ASOCIADO A CIRROSIS
- HIGADO PEQUEÑO E IRREGULAR
- ASCITIS
- ESPLENOMEGALIA
- COLATERALES PORTOSISTEMICAS
- GENERALMENTE HIPERECOICOS
- PUEDE PRESENTAR NECROSIS CENTRAL Y FIBROSIS.
- INVADE VENA PORTA

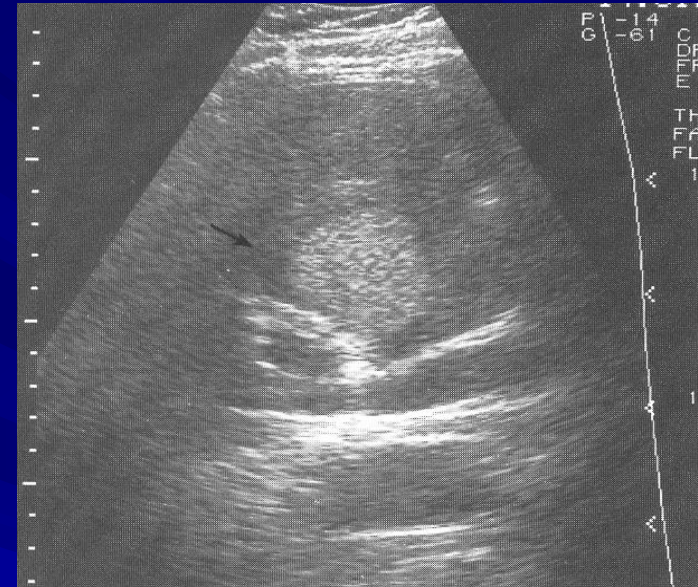
# CARCINOMA HEPATOCELULAR



- ALFAFETOPROTEINA ELEVADA



# CARCINOMA HEPATOCELULAR



**FIBROLAMELAR.**

**PACIENTES JOVENES  
SIN HEPATOPATIA**

**MASA HIPERECOICA, CON CALCIFICACIONES  
ALFAFETOPROTEINA NORMAL**

# ABSCESOS HEPATICOS

**ETIOLOGIA**

**AMIBIANOS**

**PIOGENOS**

**DISEMINACION:**

**ARTERIA HEPATICA**

**VENA PORTA**

# ABSCESOS HEPATICOS

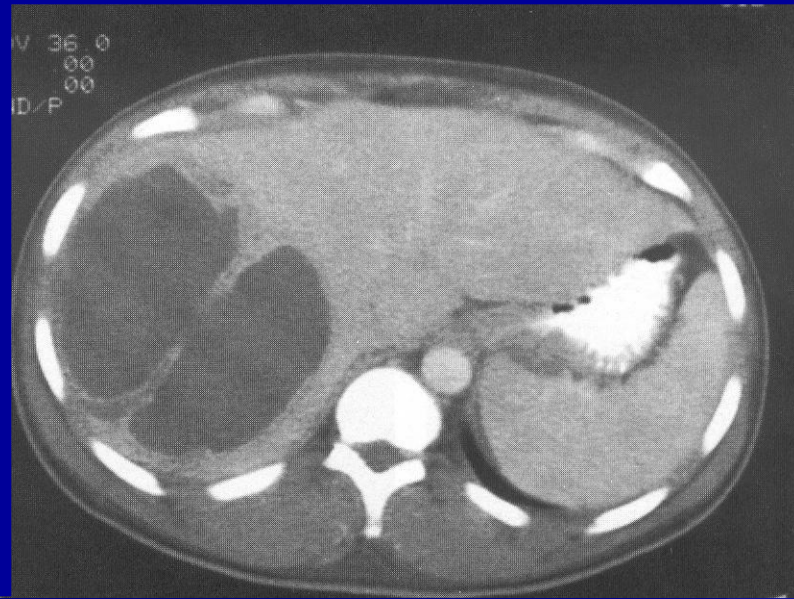
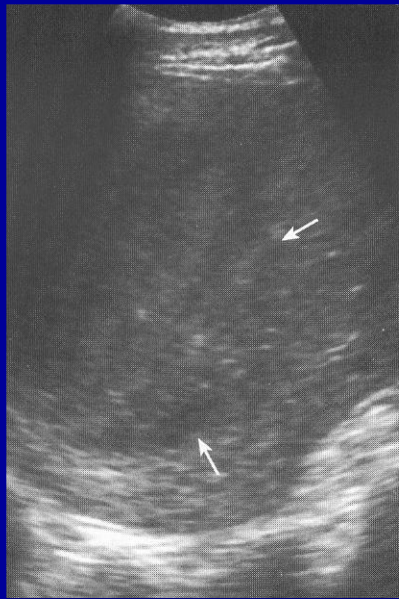## PIOGENOS:

- MULTIPLES
- GERMENES ANAEROBIOS O MEZCLA DE AMBOS
- A/ E. COLI
- N/ ESTAFILOCOCO
- PRESENTAN GAS
- HETEROGENEOS
- HIPOECOICOS

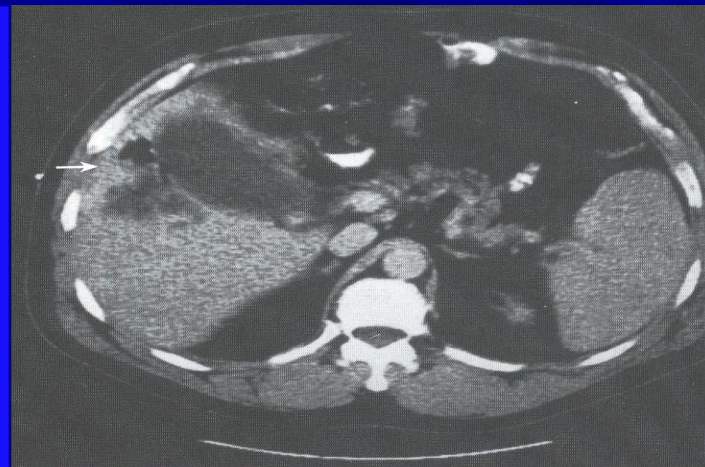
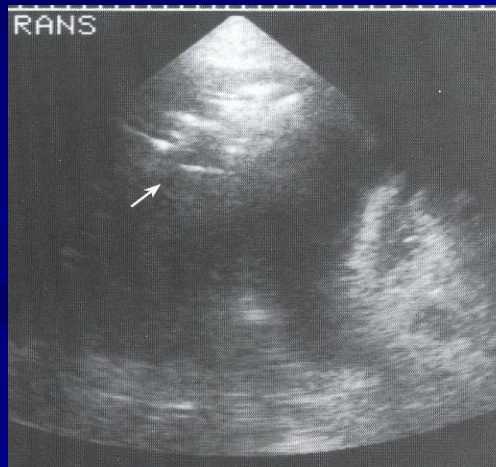
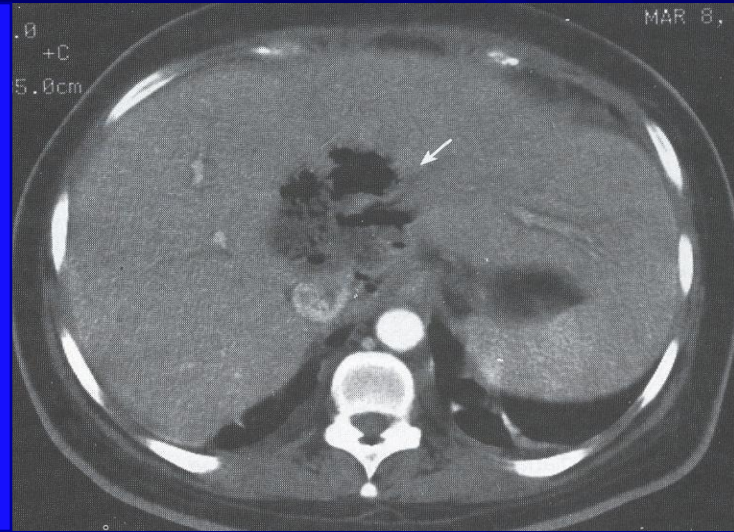
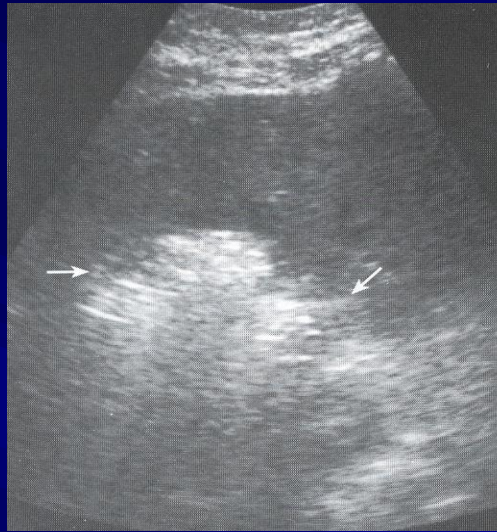
## AMIBIANOS:

- UNICO
- LOBULO DERECHO
- ENTAMOEBIA HISTOLYTICA
- NO PRESENTAN GAS
- HETEROGENEOS
- HIPOECOICOS

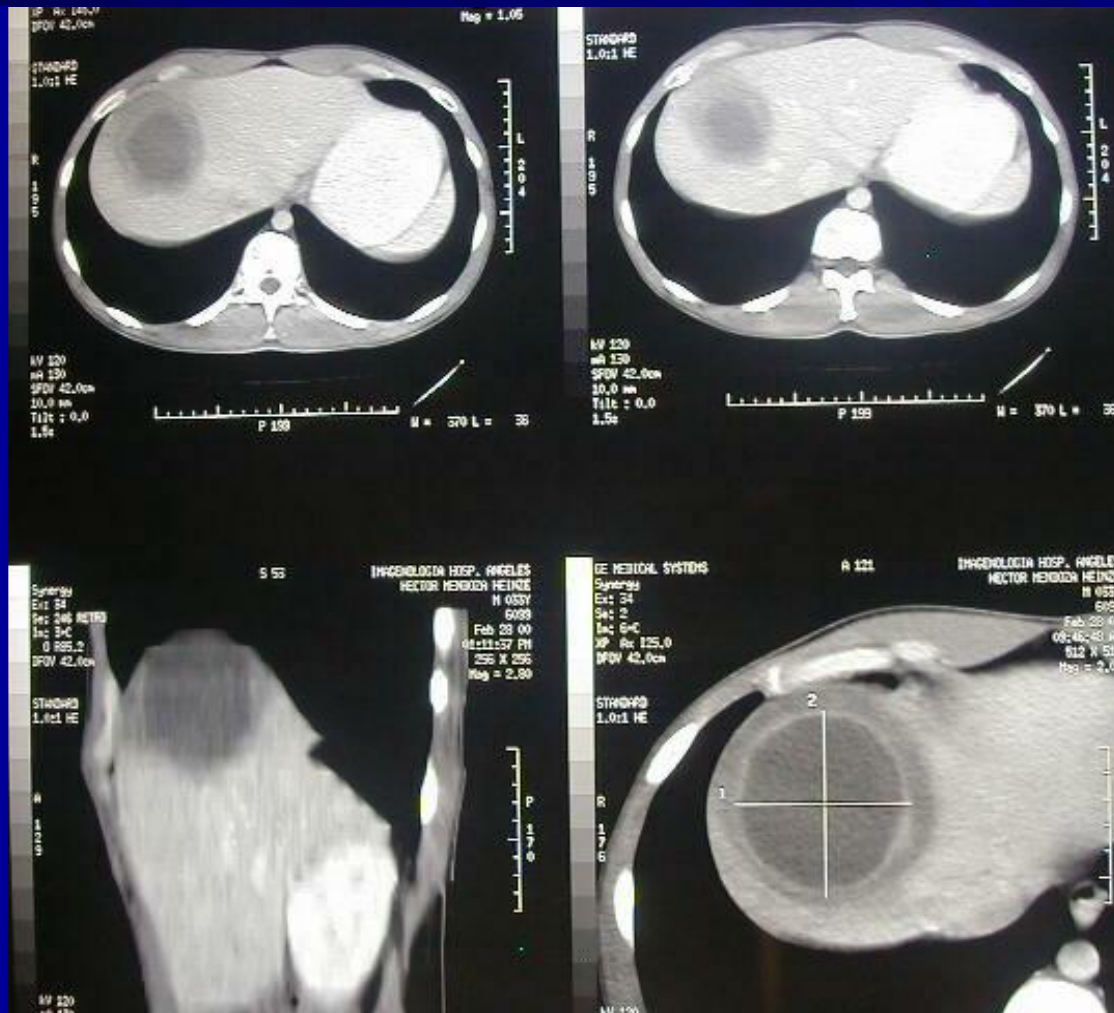
# ABSCESSO HEPATICO PIOGENO



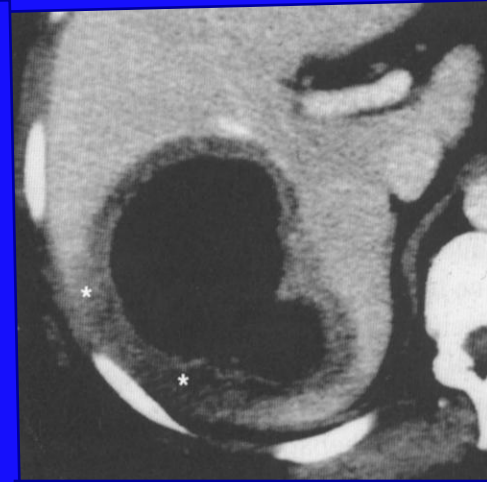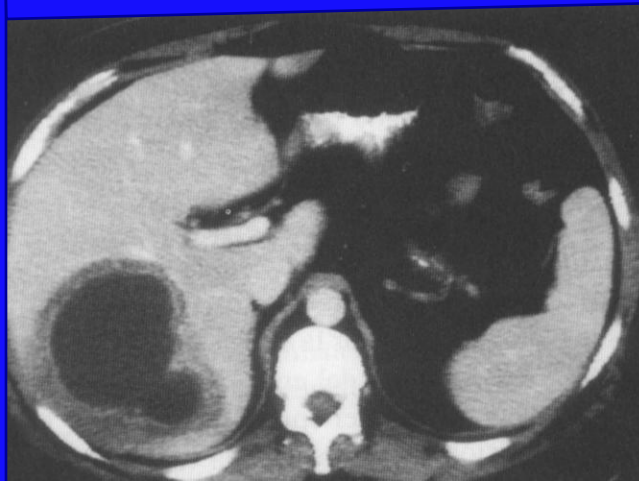
# ABSCESO HEPATICO PIOGENO



# ABSCESO HEPATICO AMIBIANO



# ABSCESSO HEPATICO AMIBIANO



# QUISTES HEPATICOS

## SIMPLES

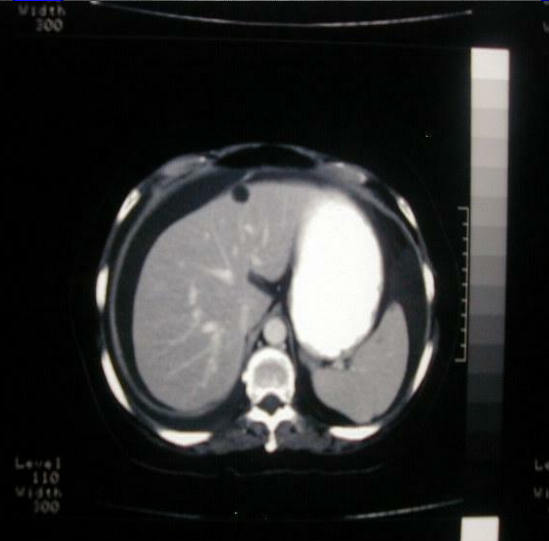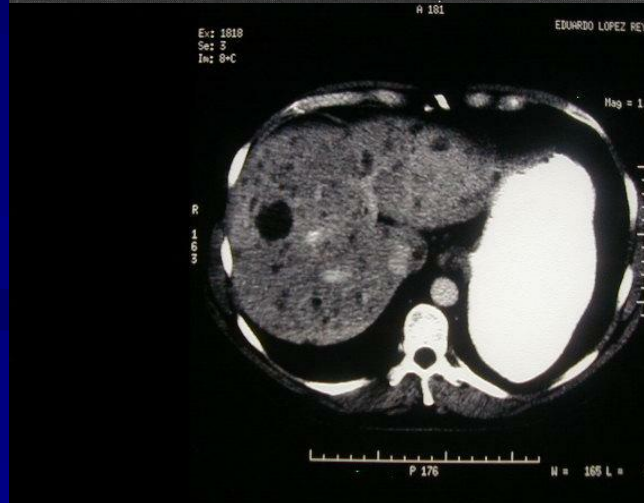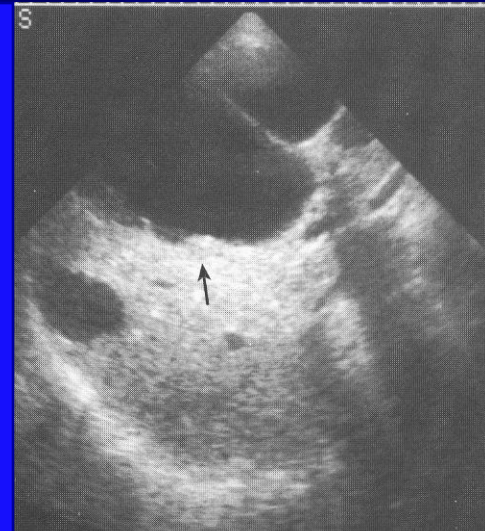
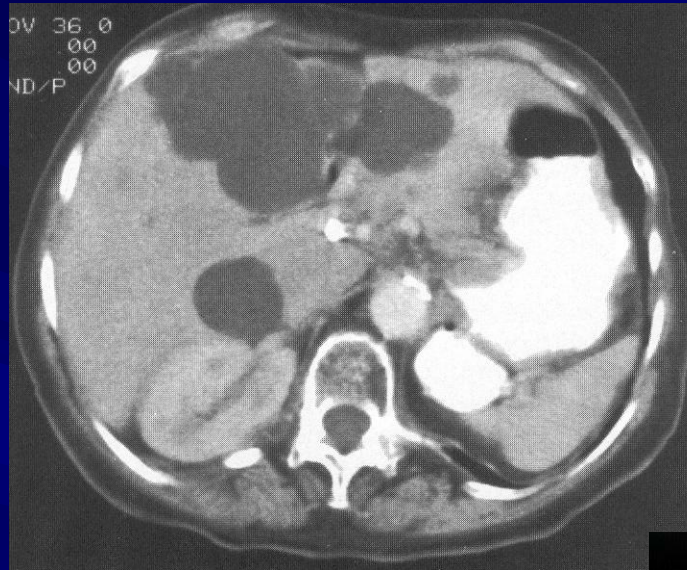
- ASINTOMATICOS
- UNICOS O MULTIPLES
- TAMAÑO VARIABLE
- ANECOICOS
- PARED DELGADA
- CON REFUERZO POSTERIOR

## COMPLICADO

- HEMORRAGIA O INFECCION
- UNICOS
- TAMAÑO VARIABLE
- HIPOECOICOS
- PARED GURESA



# QUISTES HEPATICOS SIMPLES



# HIGADO GRASO

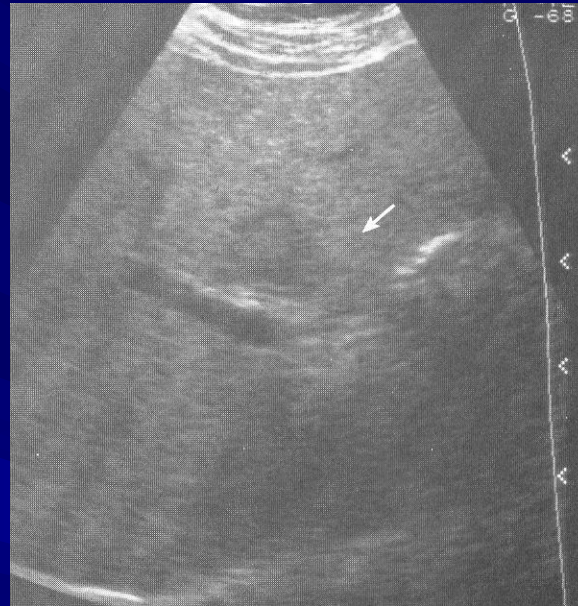**\*ACUMULACION DE TRIGLICERIDOS  
EN LOS HEPATOCITOS**

**CAUSAS:**



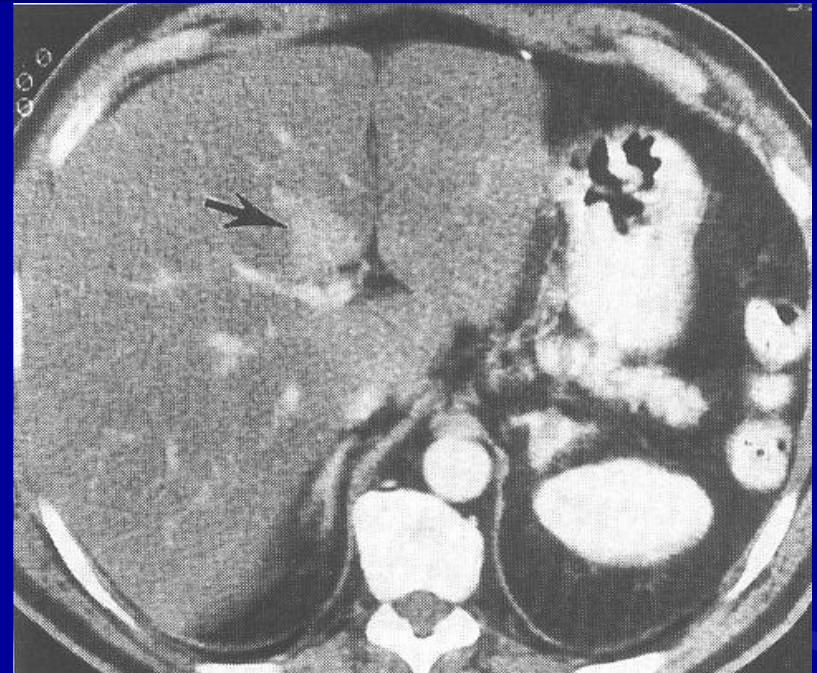
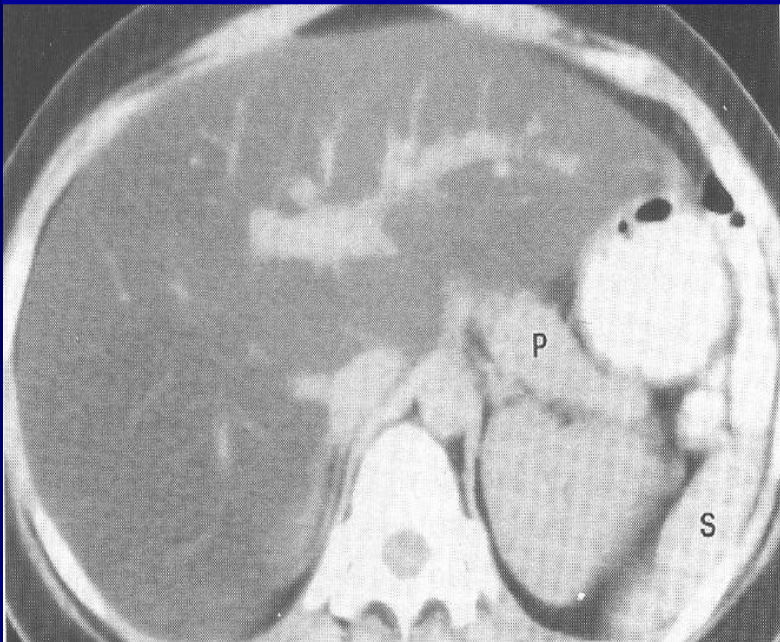
- **OBESIDAD**
- **ALCOHOLISMO**
- **MALNUTRICIÓN**
- **USO DE ESTEROIDES**
- **TOXICOS HEPATICOS**

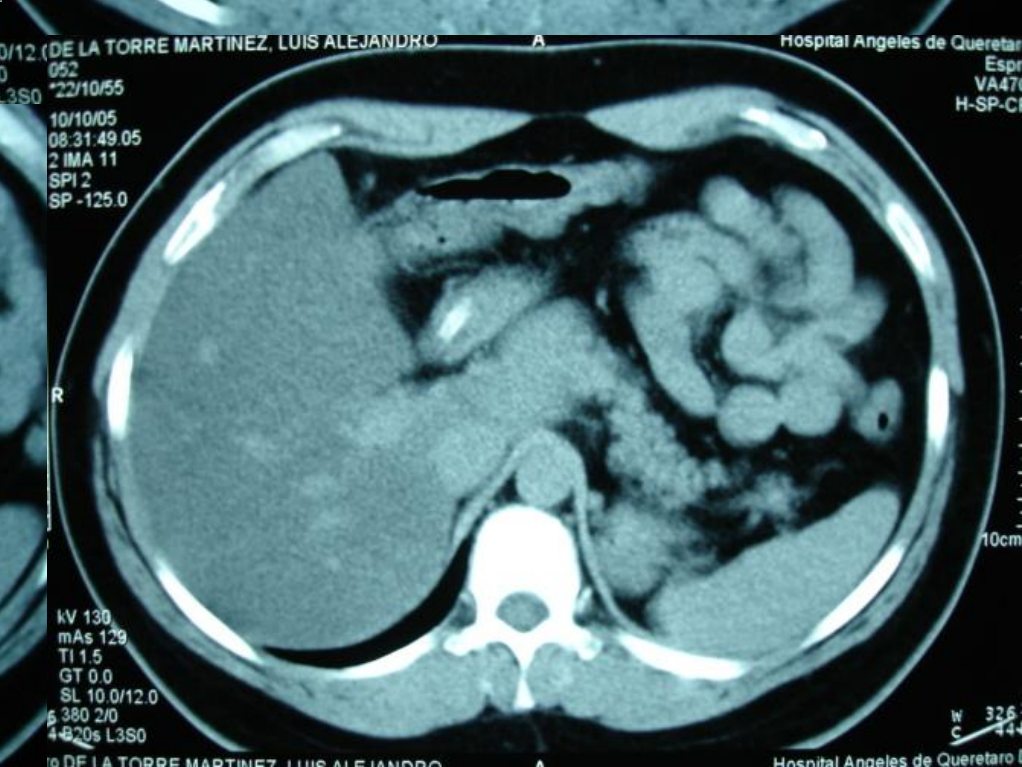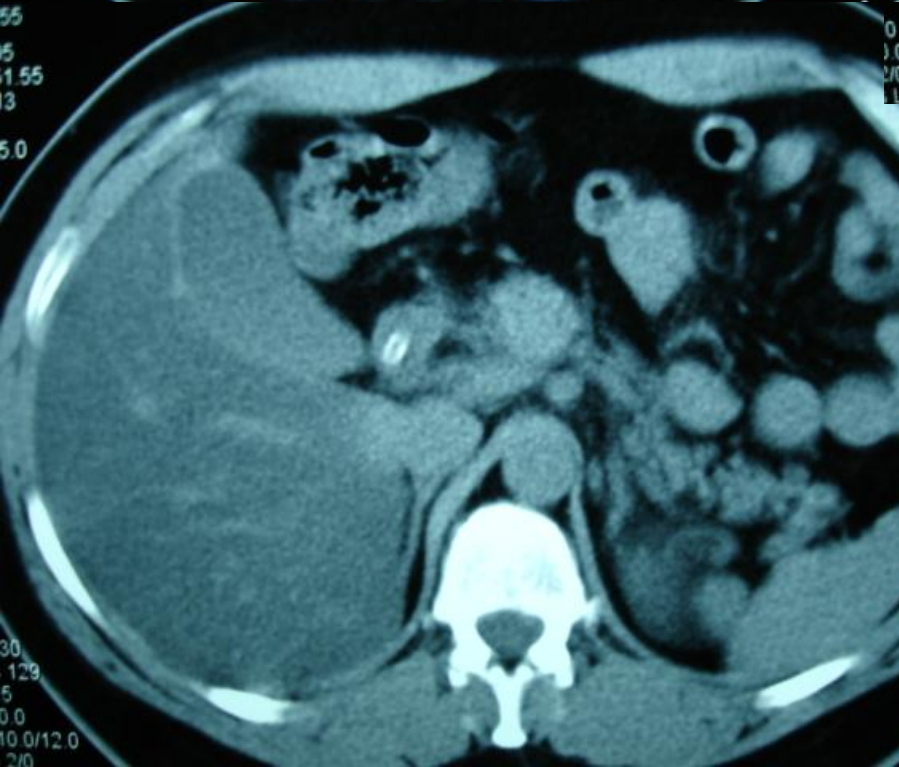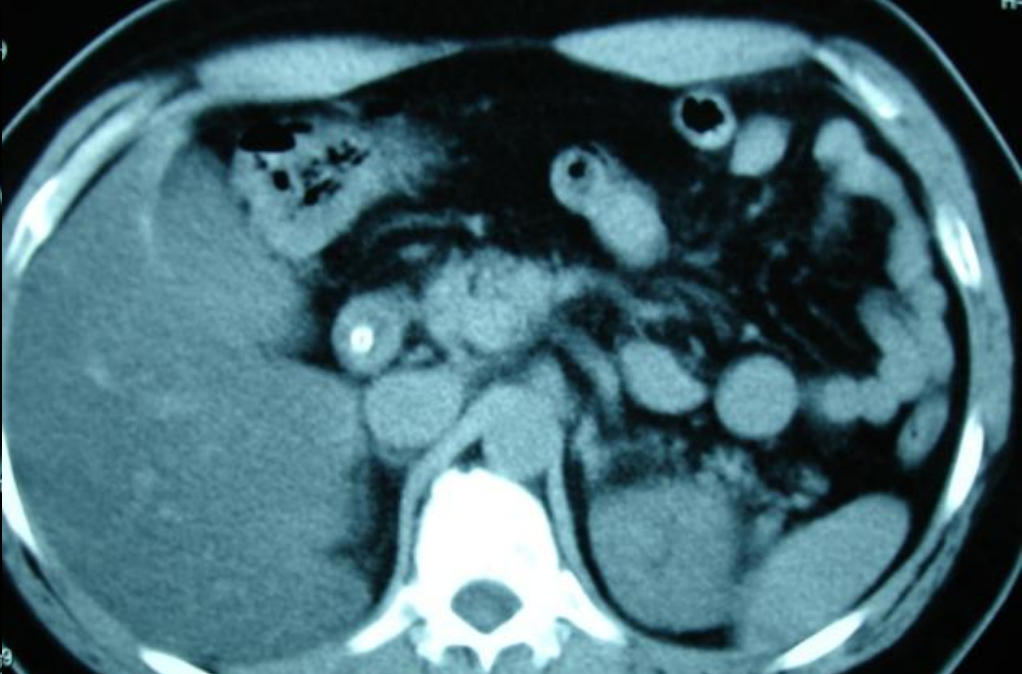
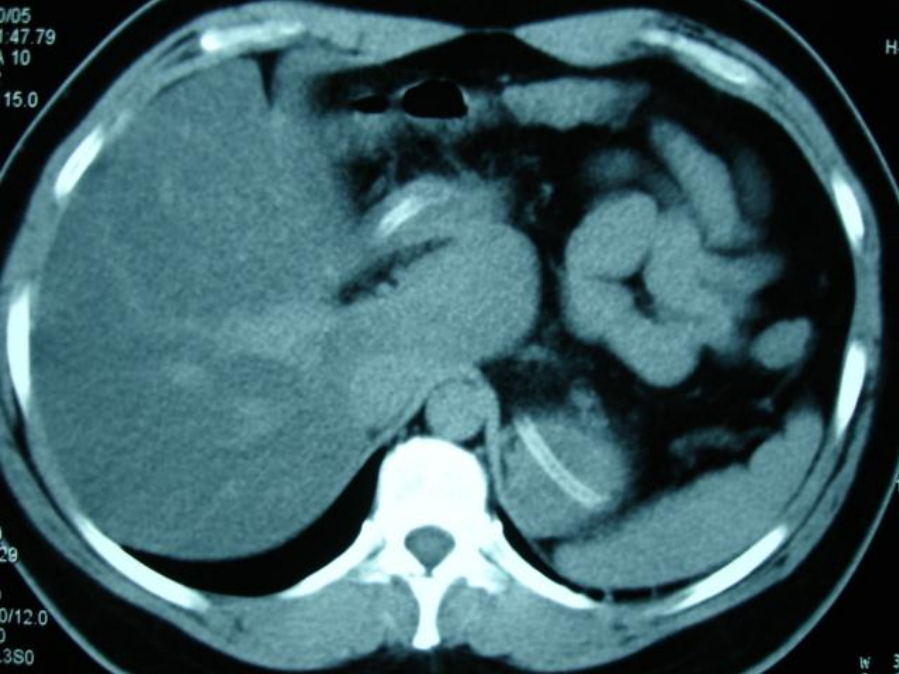# HIGADO GRASO



- **DIFUSA:** ↑ DE ECOGENICIDAD DEL HIGADO
- **FOCAL:** (HIPERECHOICA)
- **NO EFECTO DE MASA**
- **ASPECTO GEOGRAFICO**
- **DELIMITADA DE BORDES IRREGULARES**

# HIGADO GRASO

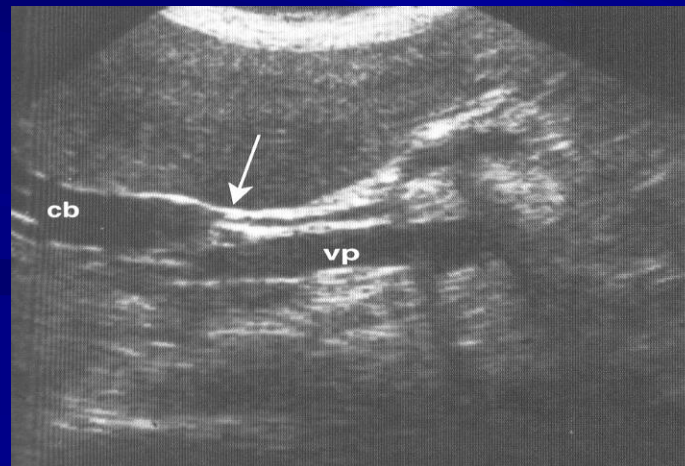
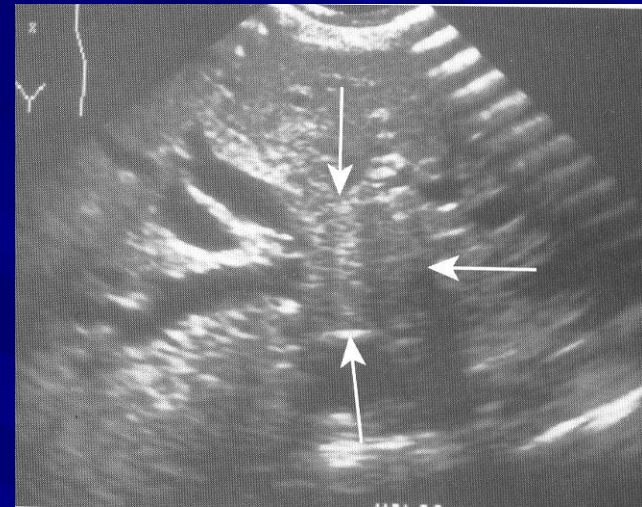
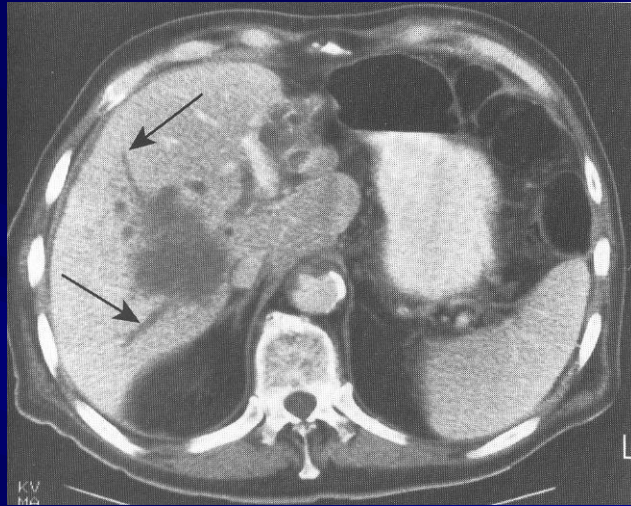




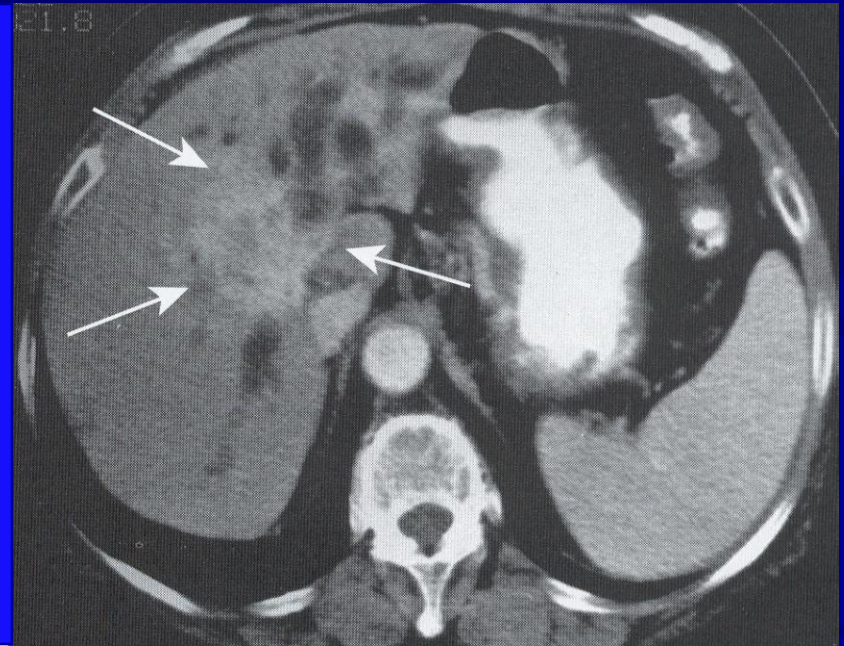
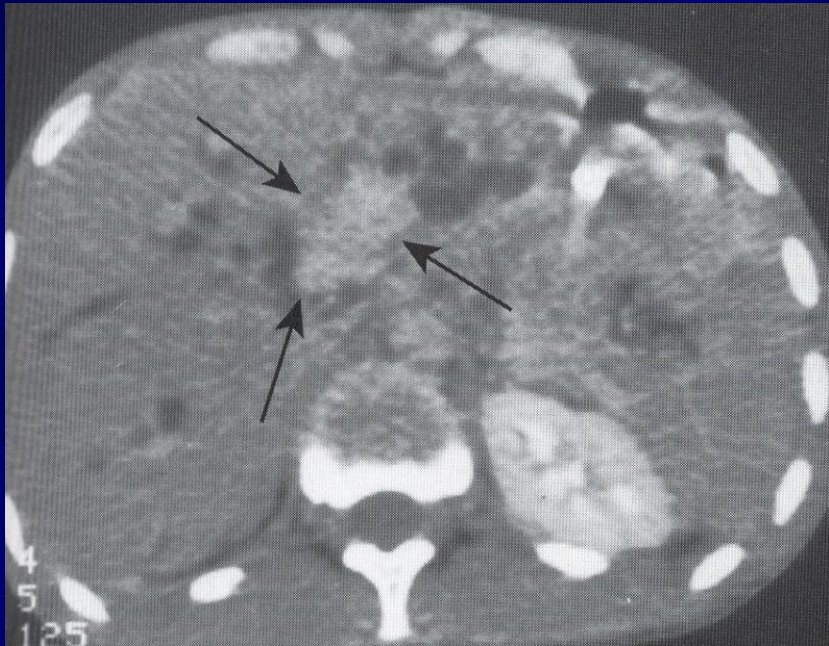
# COLANGIOCARCIONOMA

- **ORIGEN:**
- **CEL. EPITELIALES DEL ARBOL BILIAR**
- **EL 50% EN LA UNION DE LA VIA BILIAR Y EL HEPATICO COMUN(KLATSKIN)**
- **DILATACION DE LA VIA BILIAR INTRAHEPATICA DE AMBOS LOBULOS O DE UNO DE ELLOS CON EL HEPATICO COMUN DE TAMAÑO NORMAL.**
- **SIN EXISTENCIA DE LITO O CIRUGIA PREVIA**

# COLANGIOCARCINOMA



# COLANGIOCARCINOMA



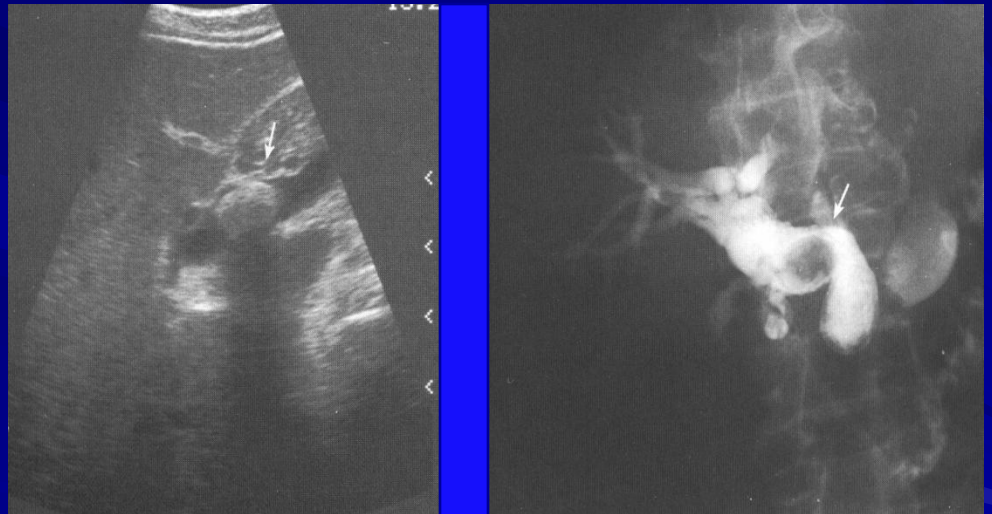
**TUMOR DE LA ENCRUCIJADA (KLATSKIN)**



# VIA BILIAR

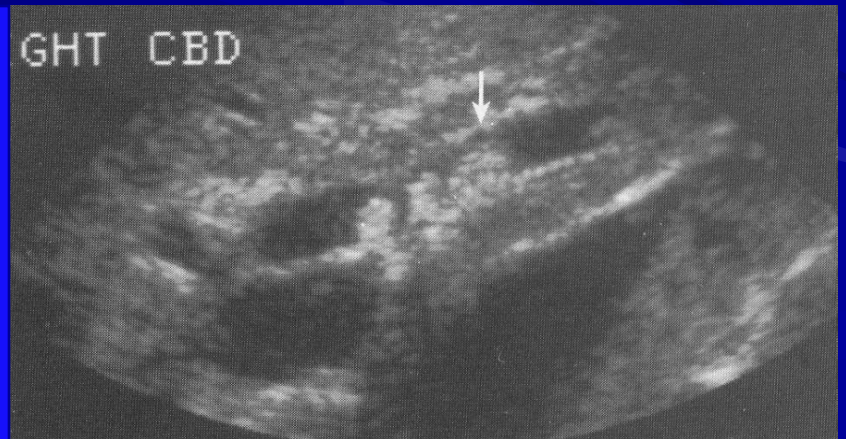
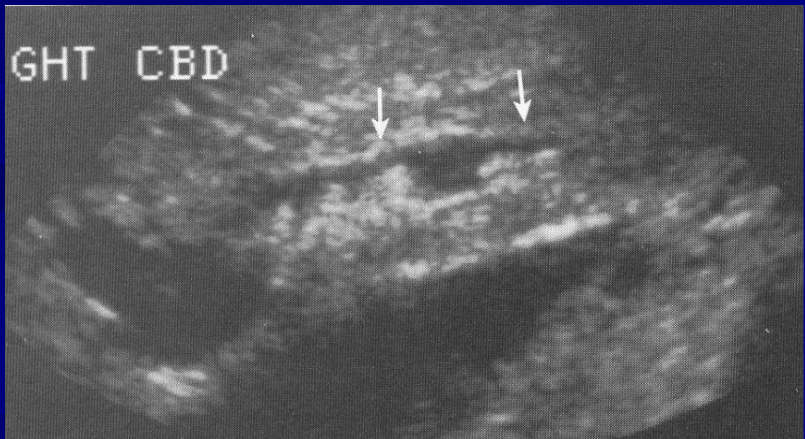
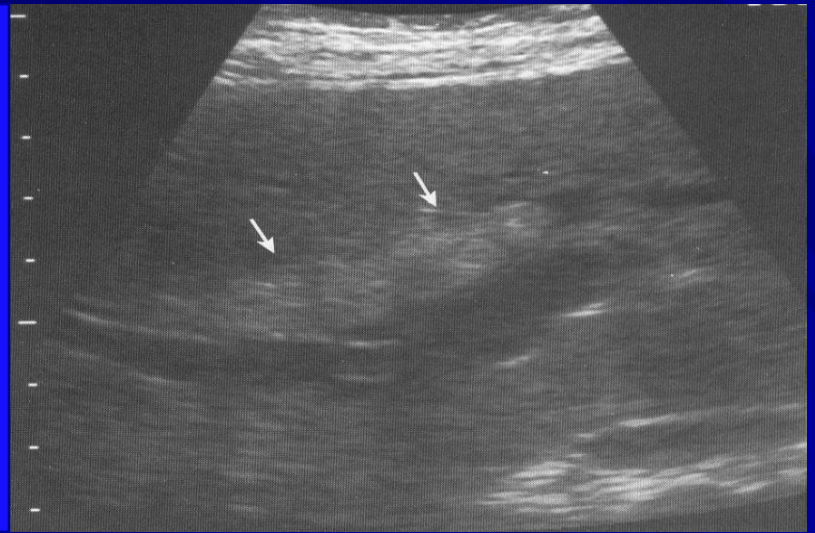
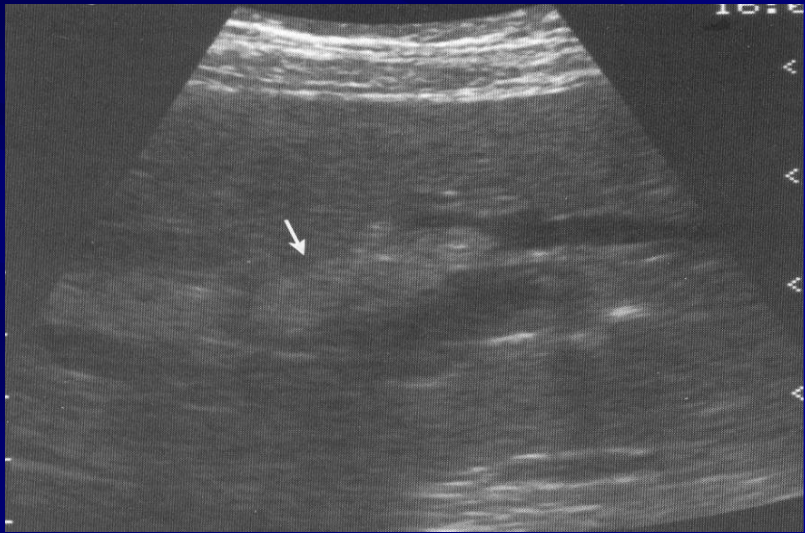
## MATERIAL DENTRO DEL SISTEMA BILIAR

- CALCULOS
- NEOPLASIAS
- LODO BILIAR
- PARASITOS
- PROTESIS O TUBOS
- AEROBILIA
- SANGRE
- MASAS FUNGOIDES



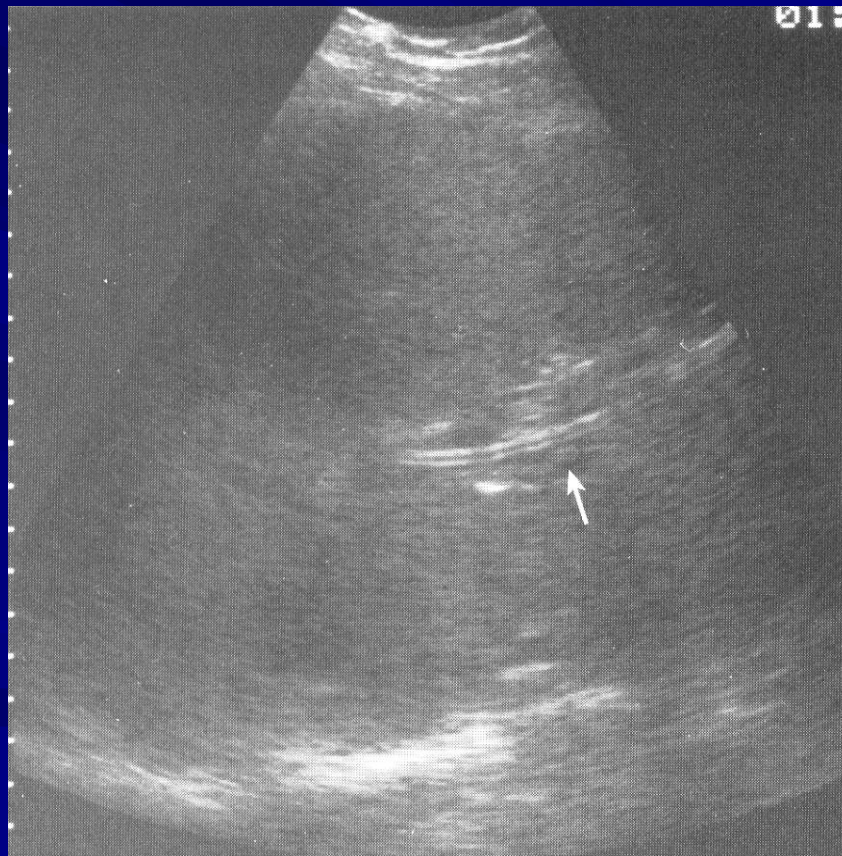
# VIA BILIAR

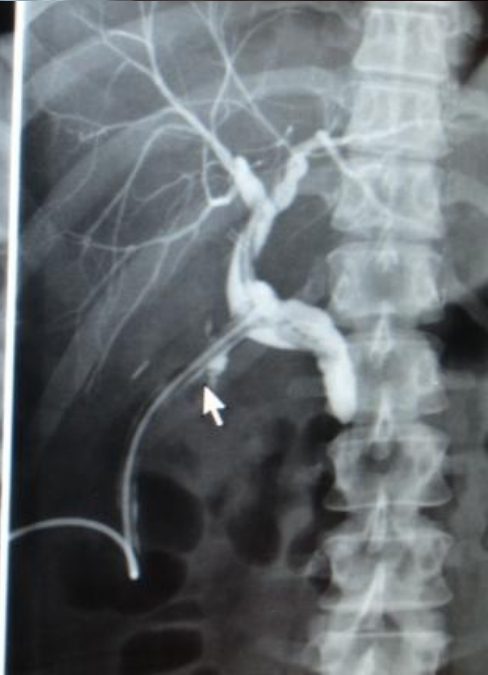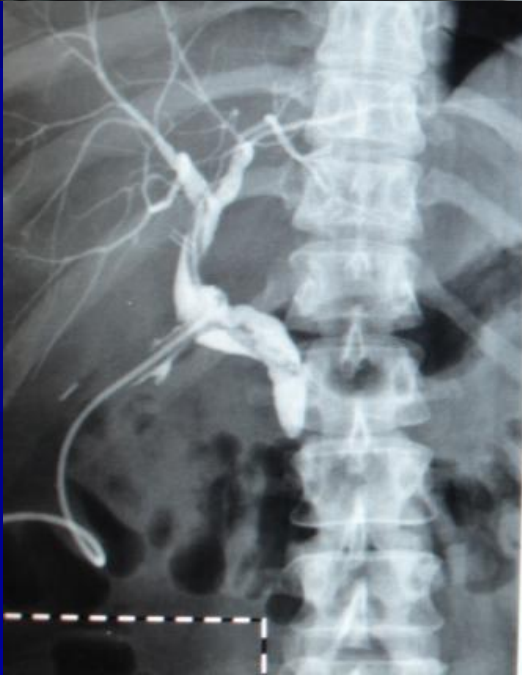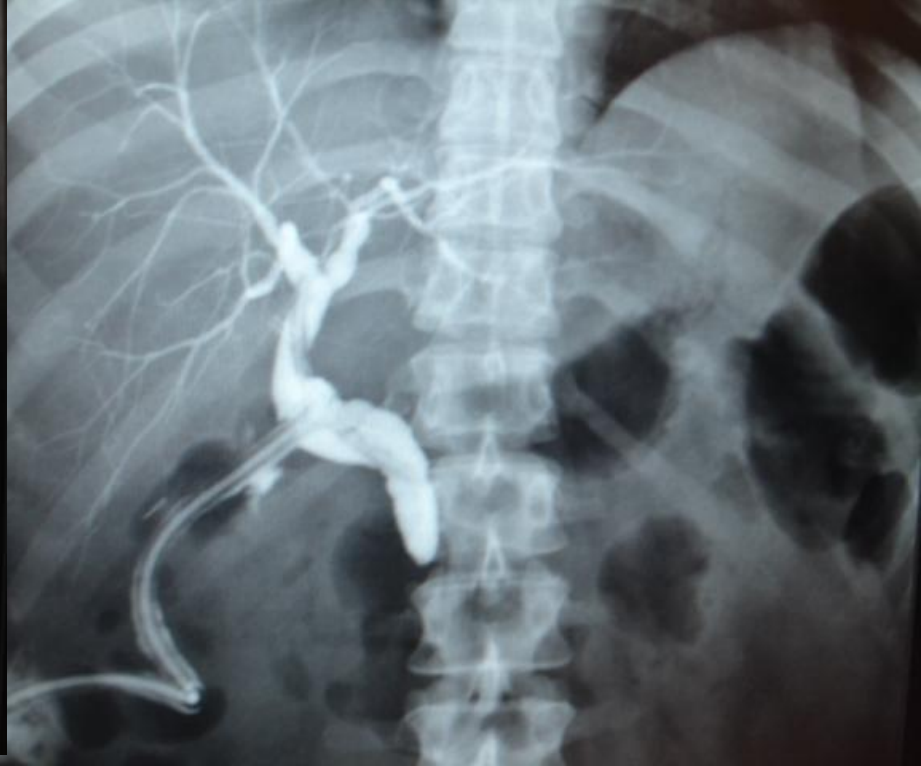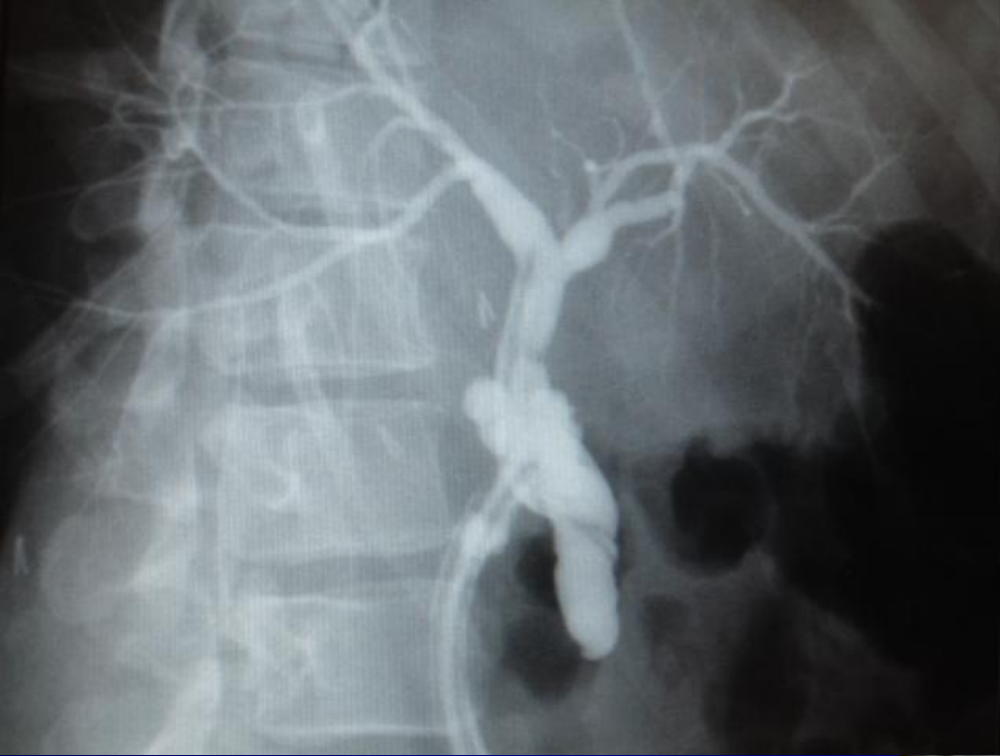## MATERIAL DENTRO DEL SISTEMA BILIAR



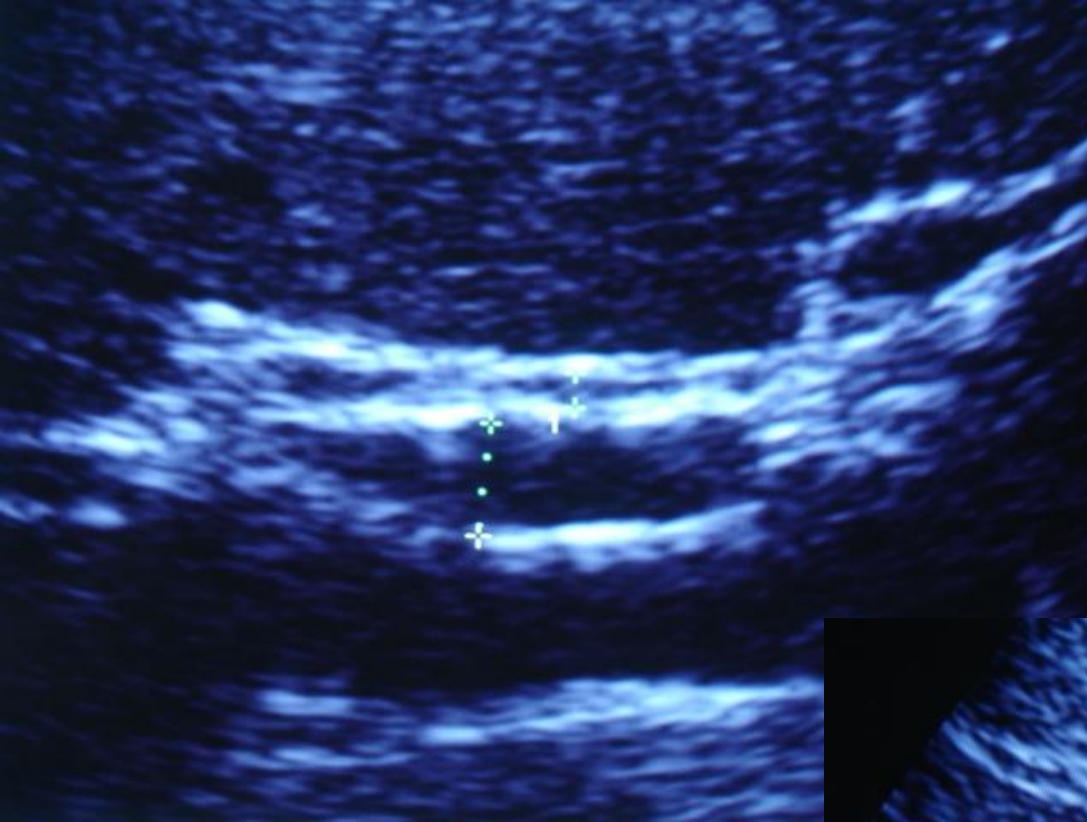
# VIA BILIAR

## MATERIAL DENTRO DEL SISTEMA BILIAR

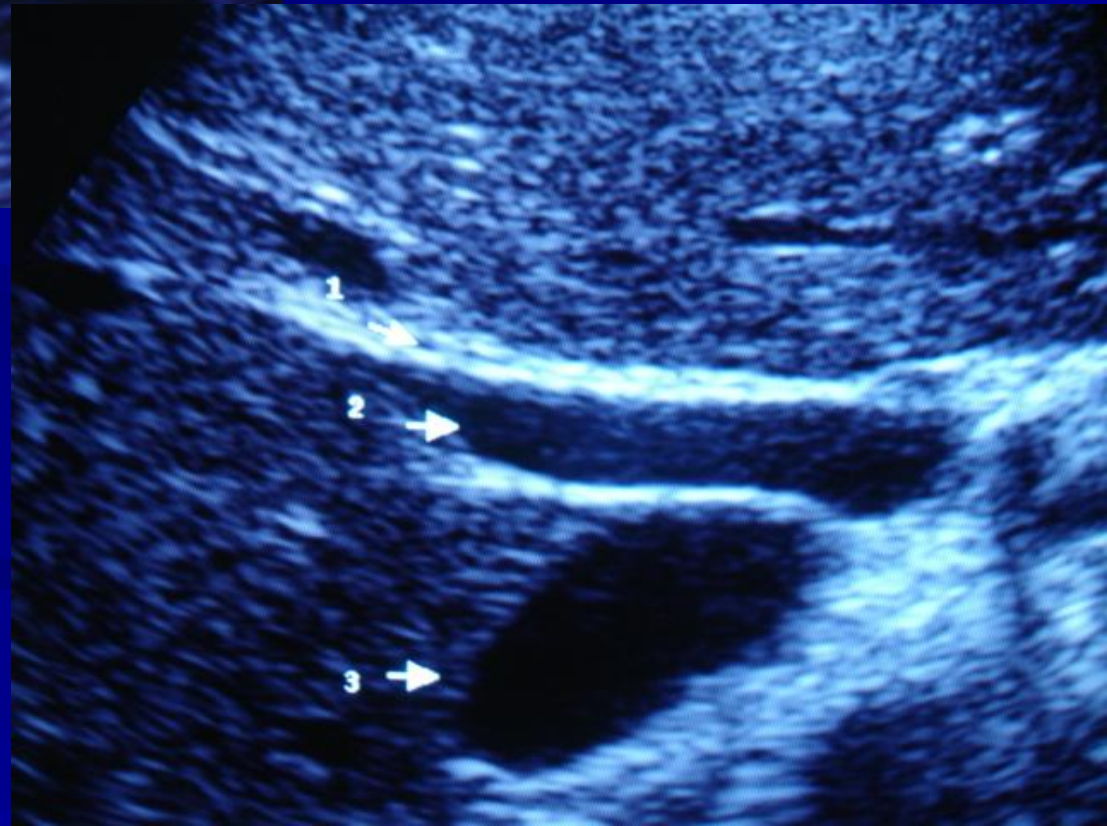




## VIA BILIAR



1. CONDUCTO BILIAR PRIMARIO
2. VENA PORTA
3. VENA CAVA



# COLECISTITIS

## *ENGROSAMIENTO DE LA PARED DE LA VESICULA*

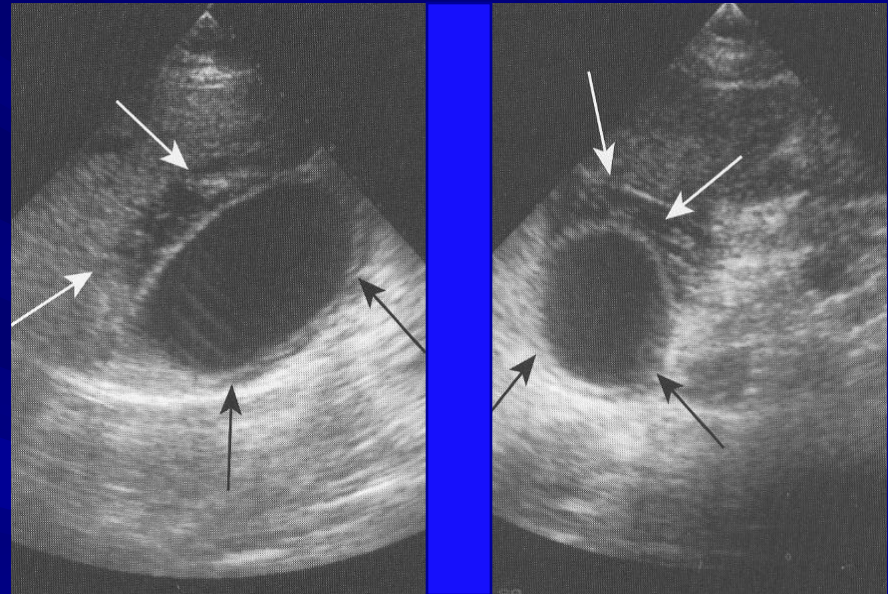
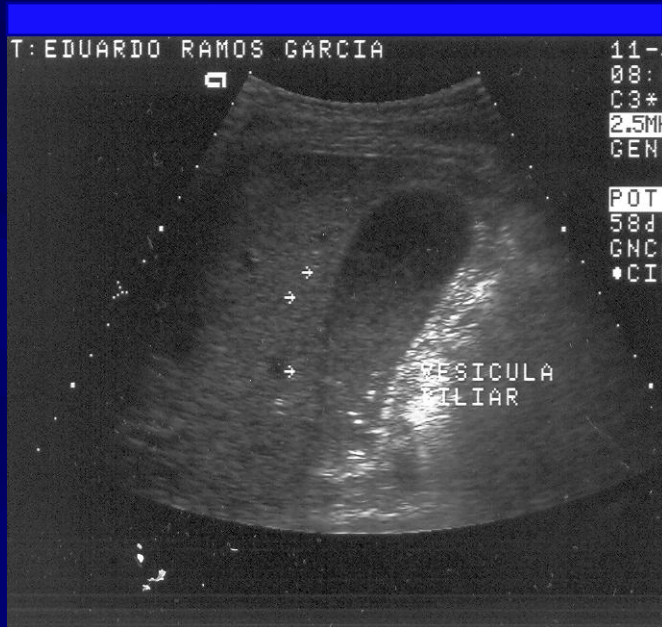### INTRINSECAS

COLECISTITIS AGUDA  
COLECISTITIS CRONICA  
ADENOMIOMATOSIS  
CARCINOMA

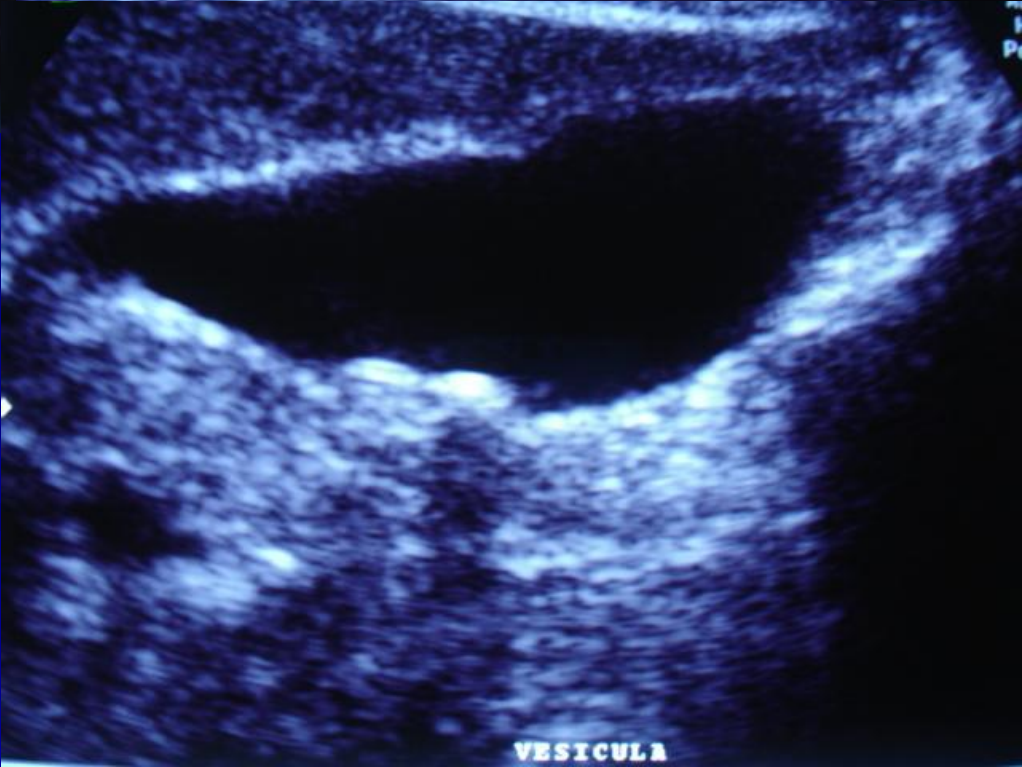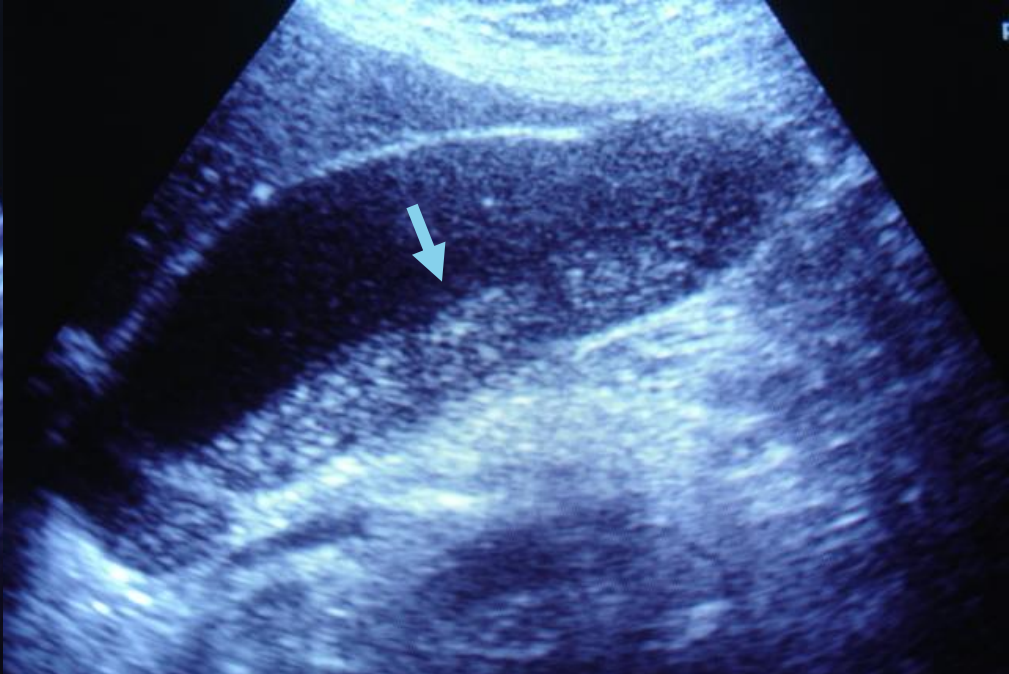
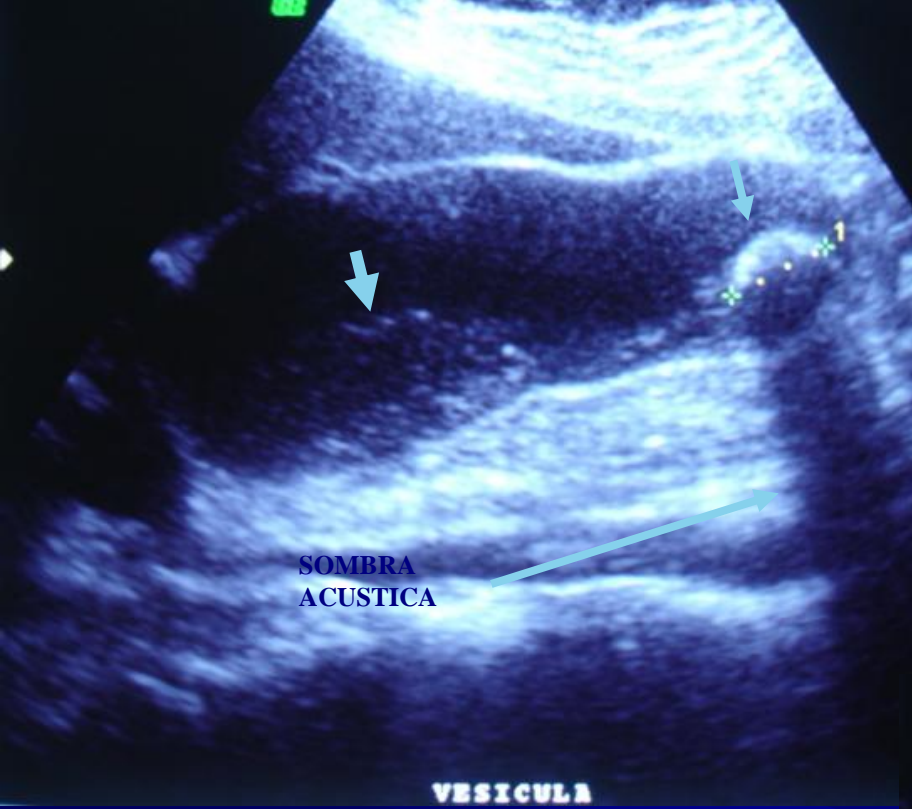
### EXTRINSECAS

ICC  
HIPOALBUMINEMIA  
PROCESOS HEPATICOS  
IR  
ASCITIS  
PANCREATITIS  
OBSTRUCCION LINFATICA

# COLECISTITIS AGUDA

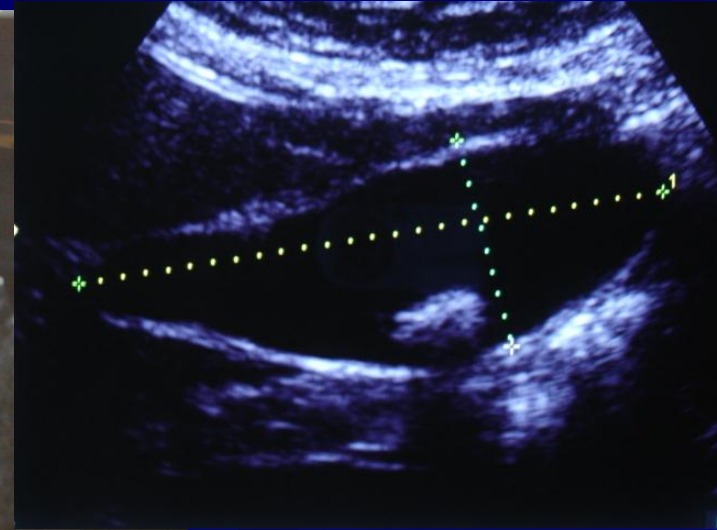
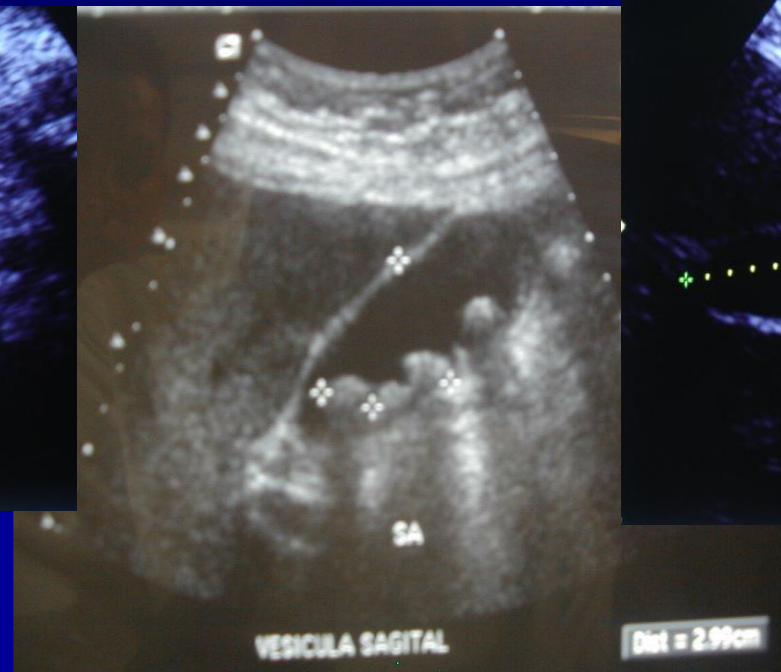
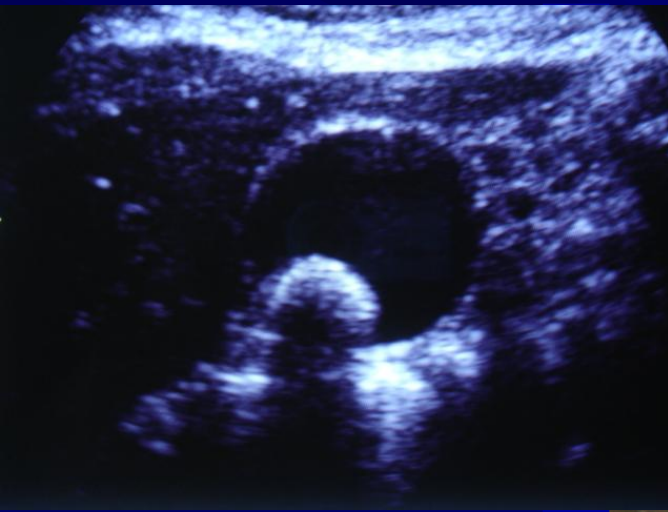

- LITIASICA
- ALITIASICA
- \*EDEMA PERIVESICULAR\*
- PARED DE 5 mm O MAS

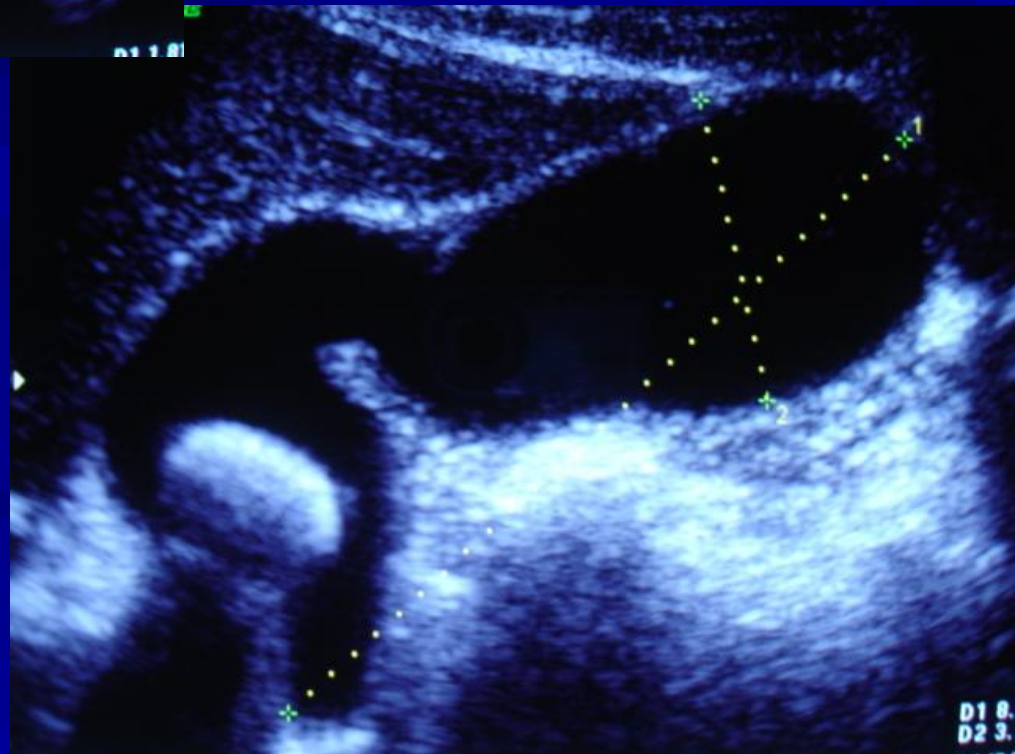
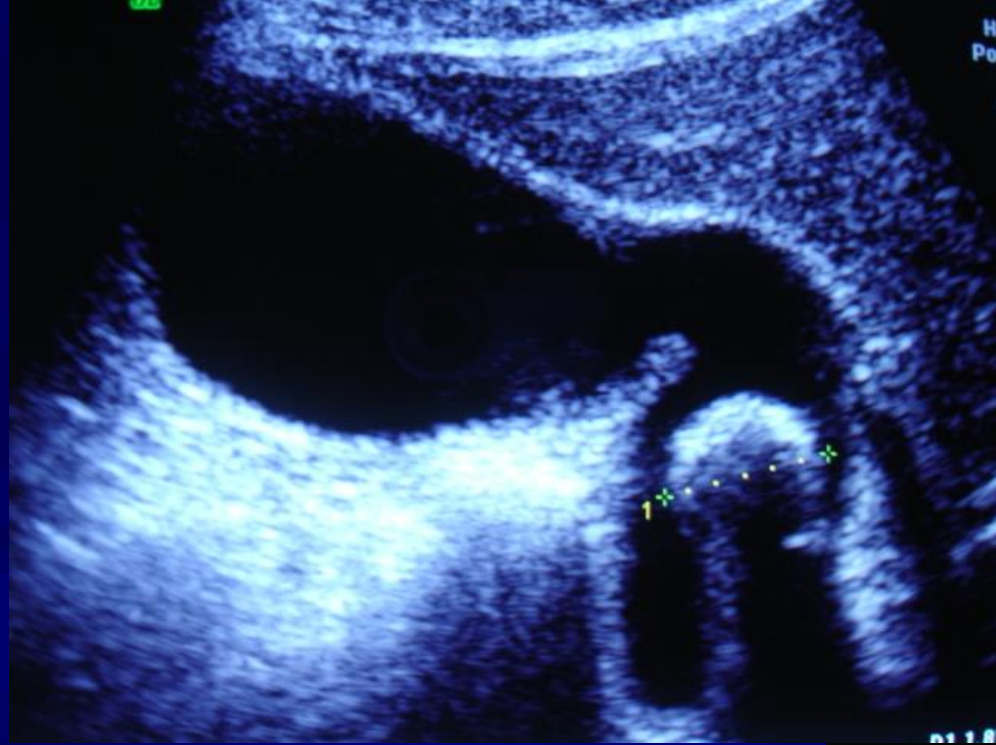



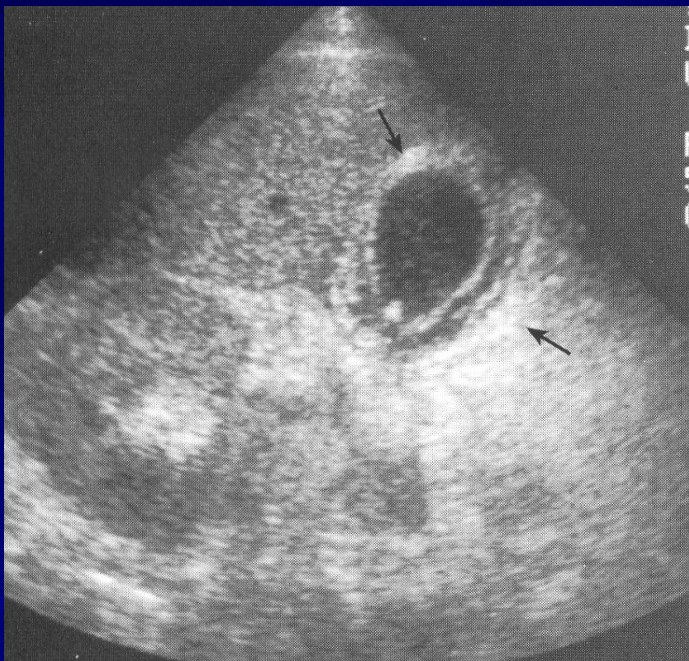
# COLECISTITIS CRONICA



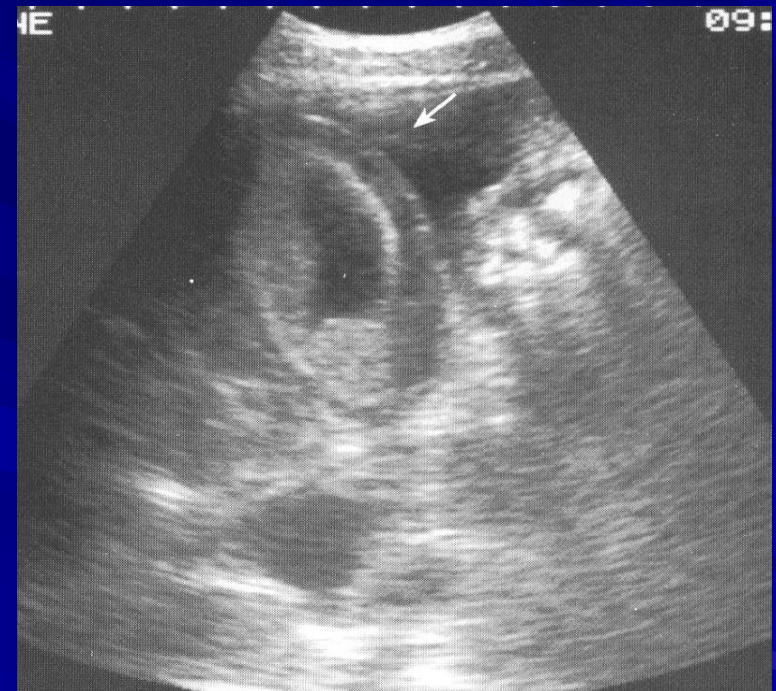- LITIASICA
- PARED DE MAS DE 3 mm
- SIN EDEMA PERIVESICULAR



# CAUSAS EXTRINSECAS DE ENGROSAMIENTO DE LA PARED VESICULAR

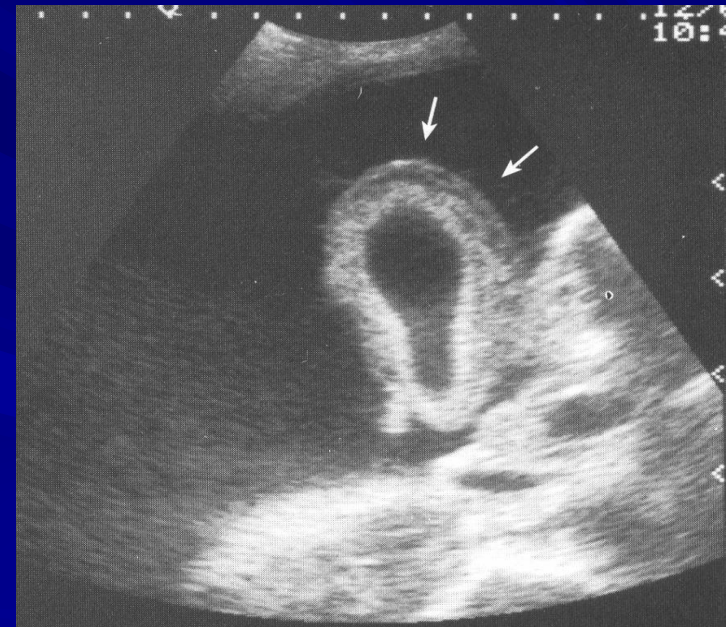
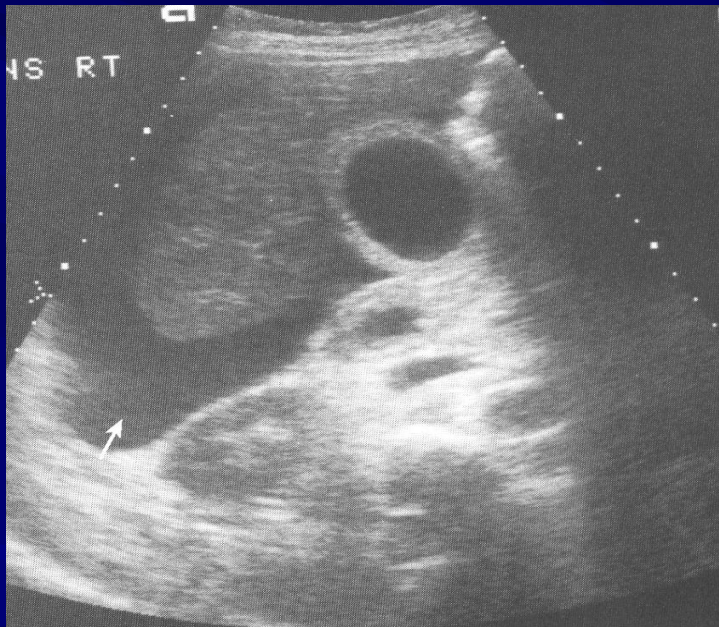

**HEPATITIS**

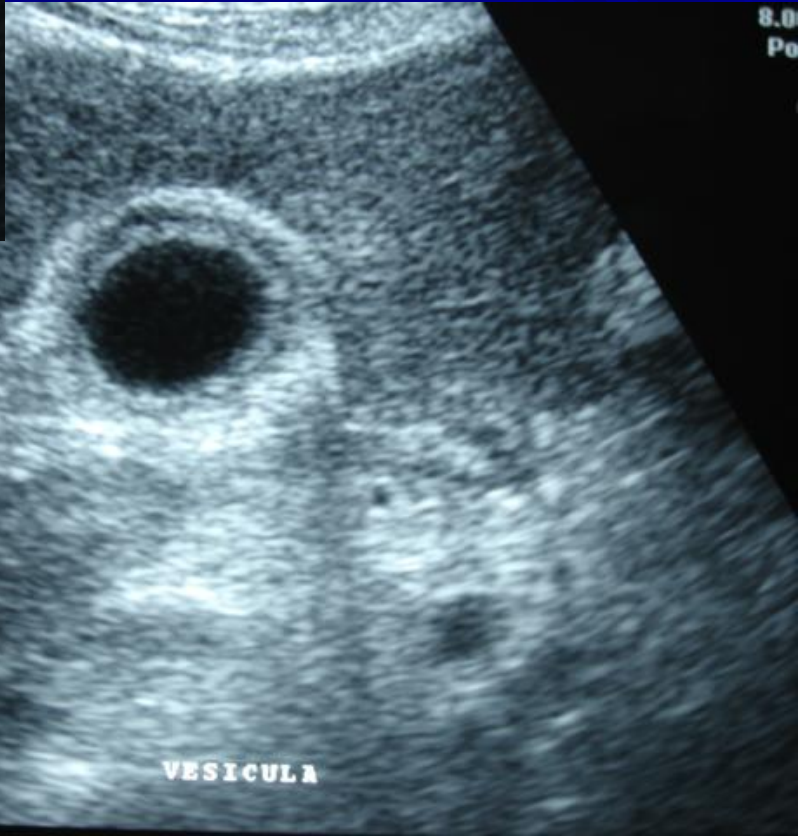
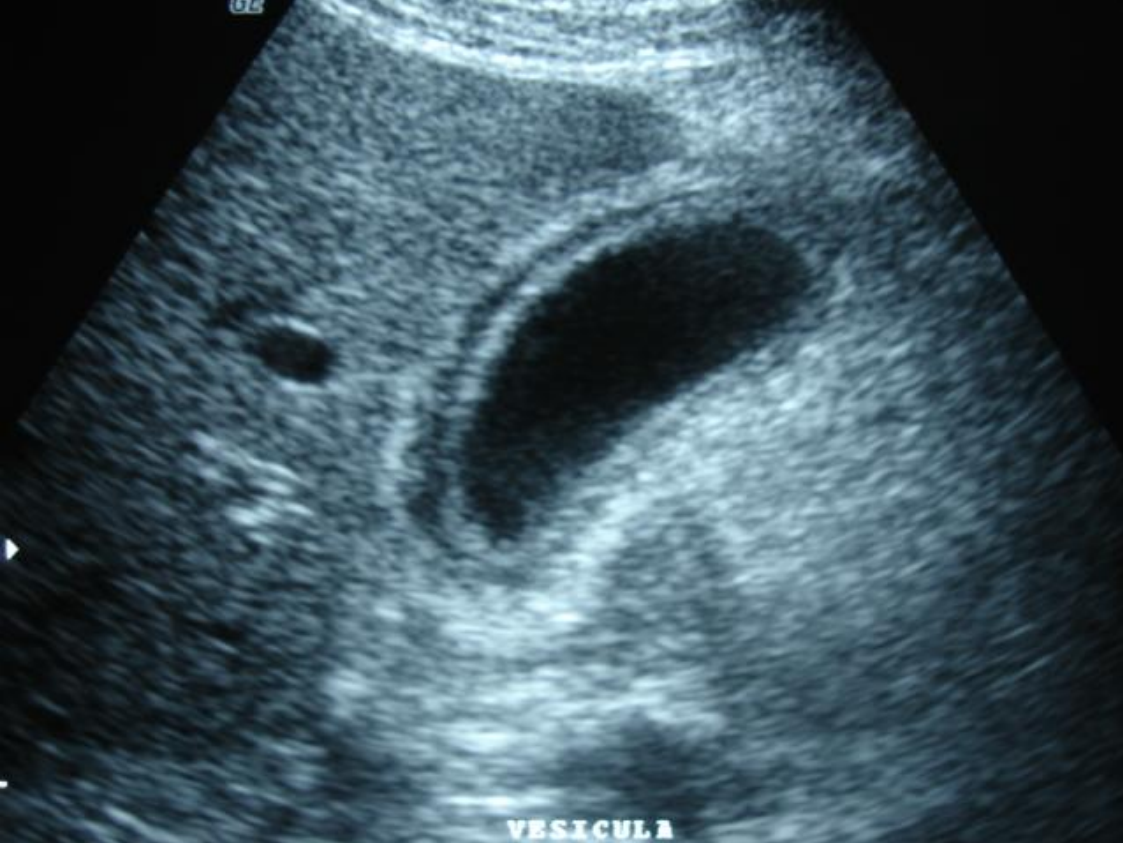
**HEPATOPATIA  
ALCOHOLICA**

# CAUSAS EXTRINSECAS DE ENGROSAMIENTO DE LA PARED VESICULAR

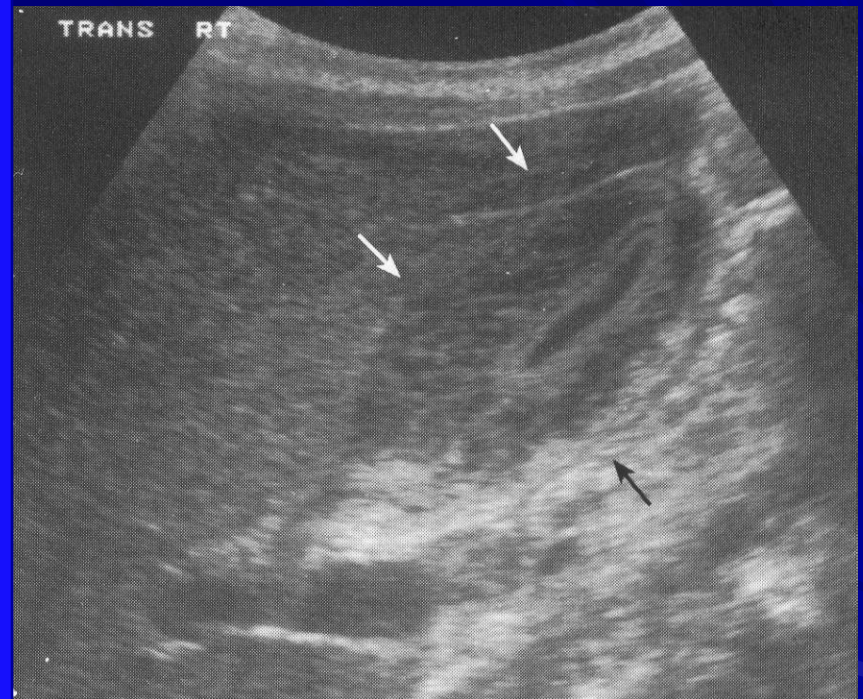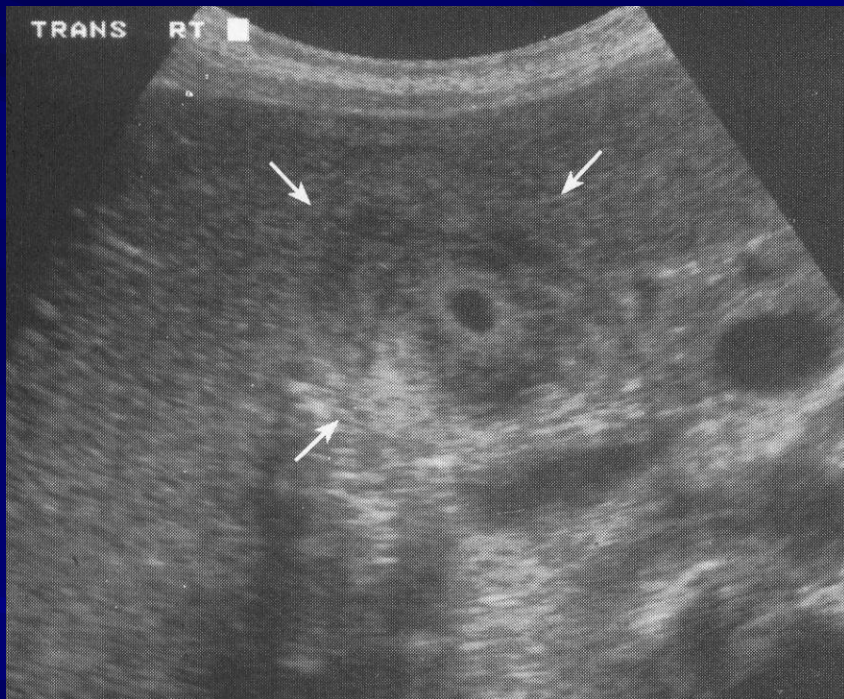


ASCITIS

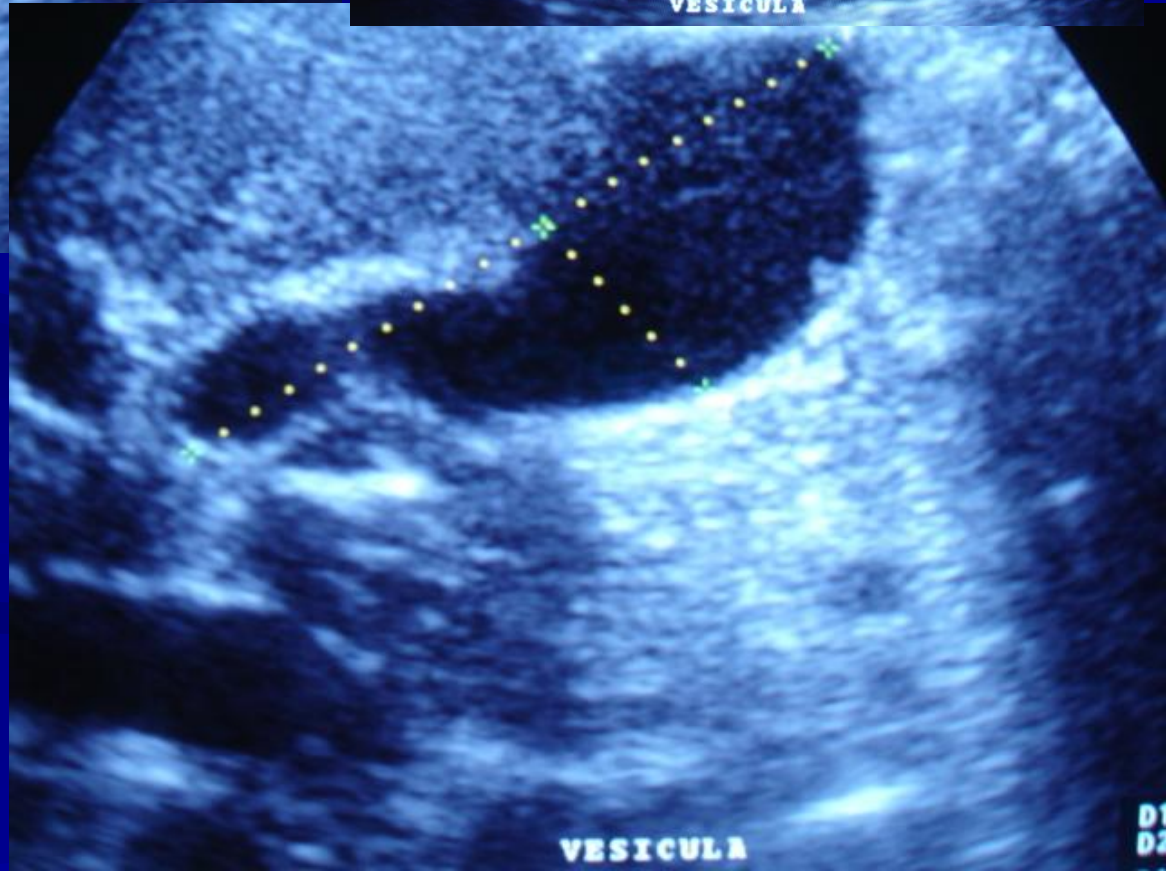
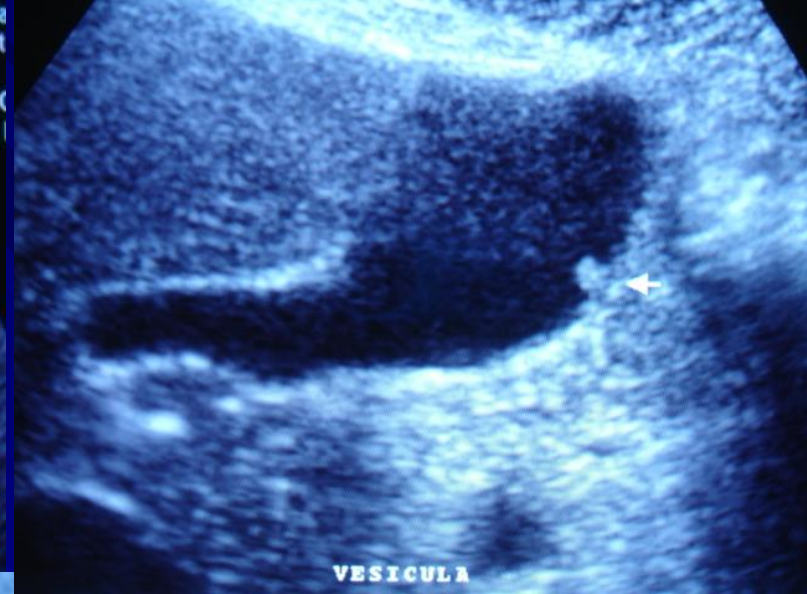
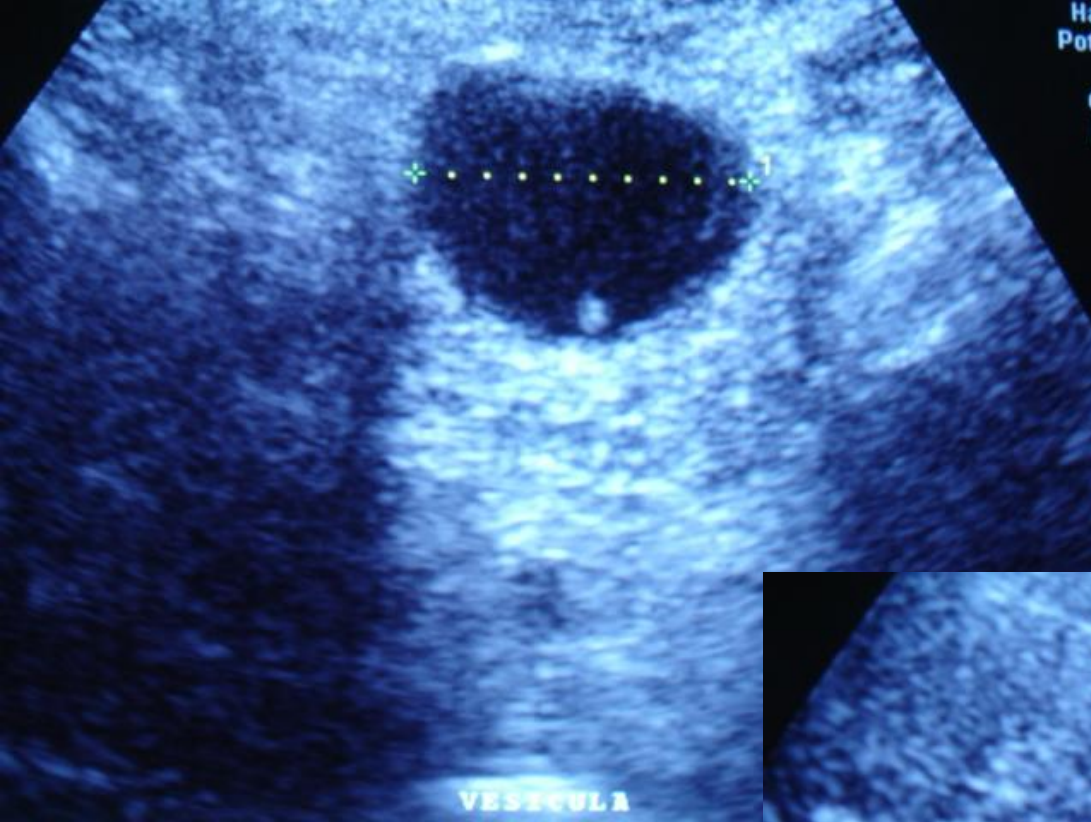ASCITIS

# CAUSAS EXTRINSECAS DE ENGROSAMIENTO DE LA PARED VESICULAR

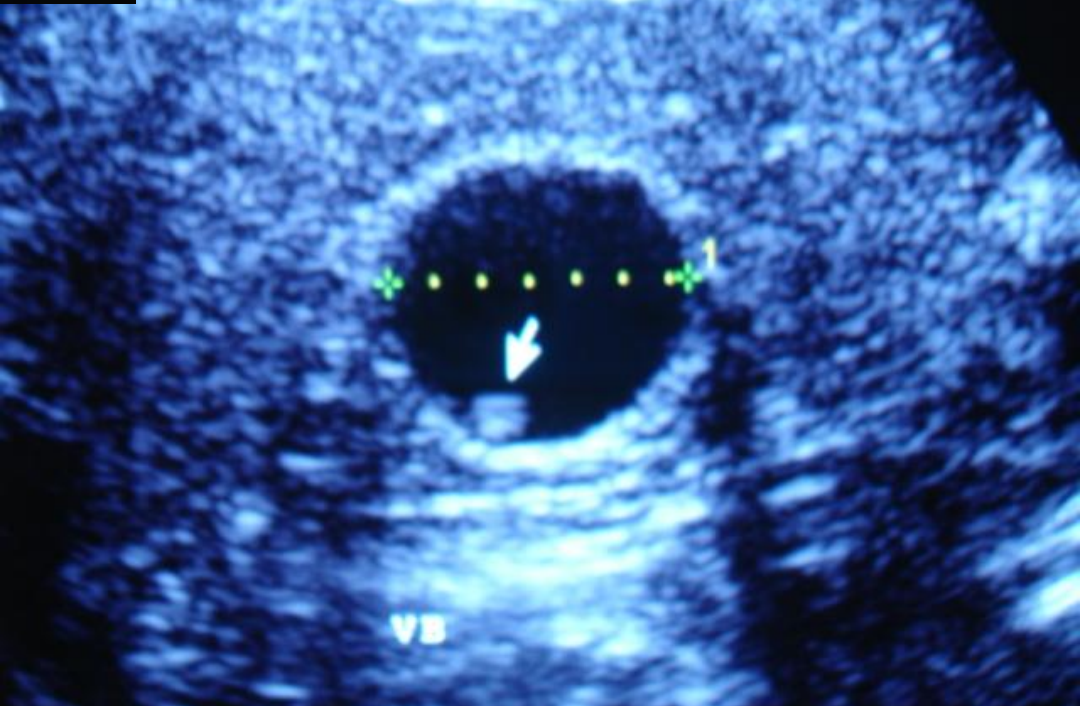
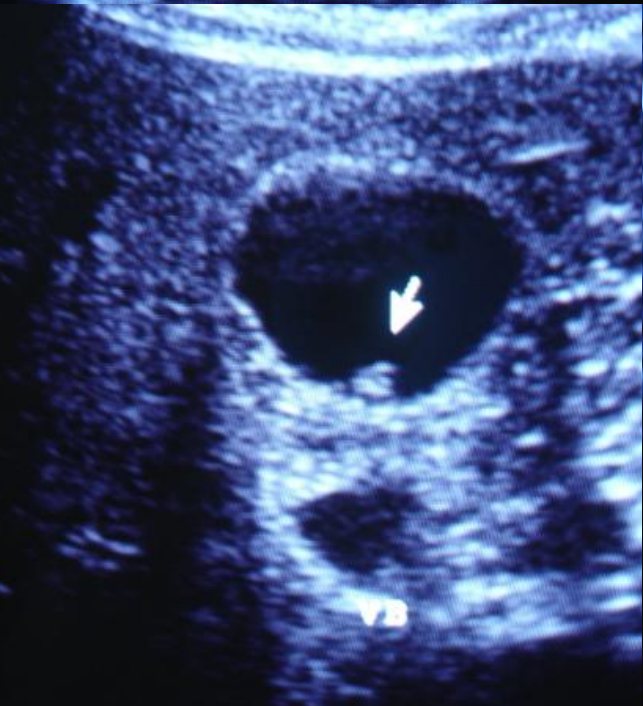
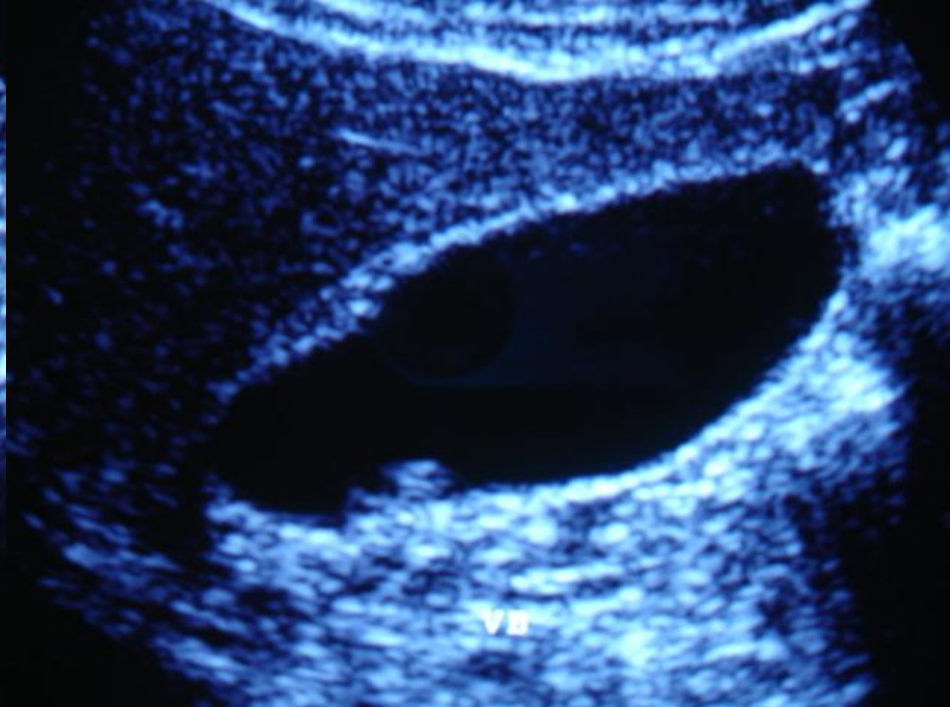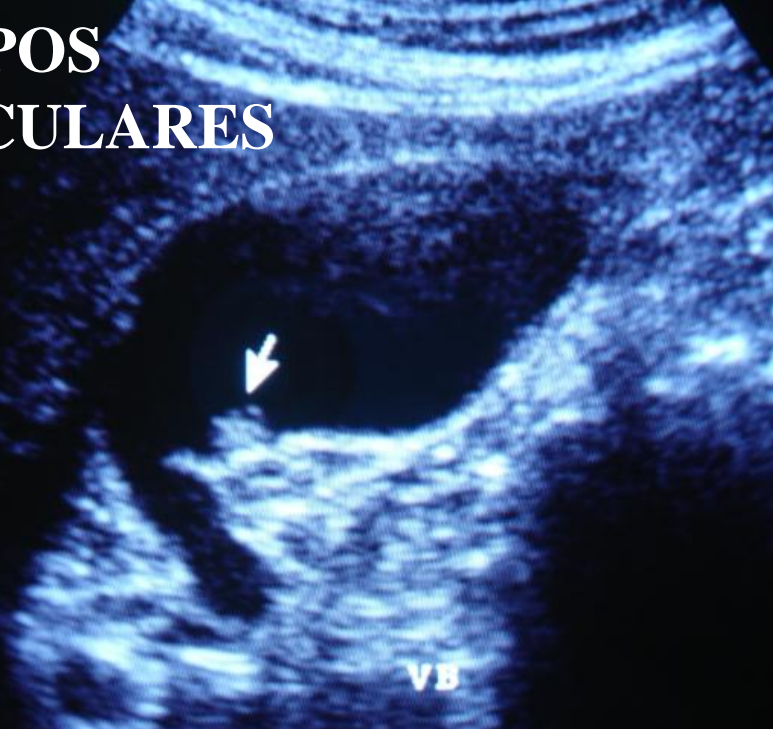INSUFICIENCIA RENAL



# POLIPOS VESICULARES

# POLIPOS VESICULARES

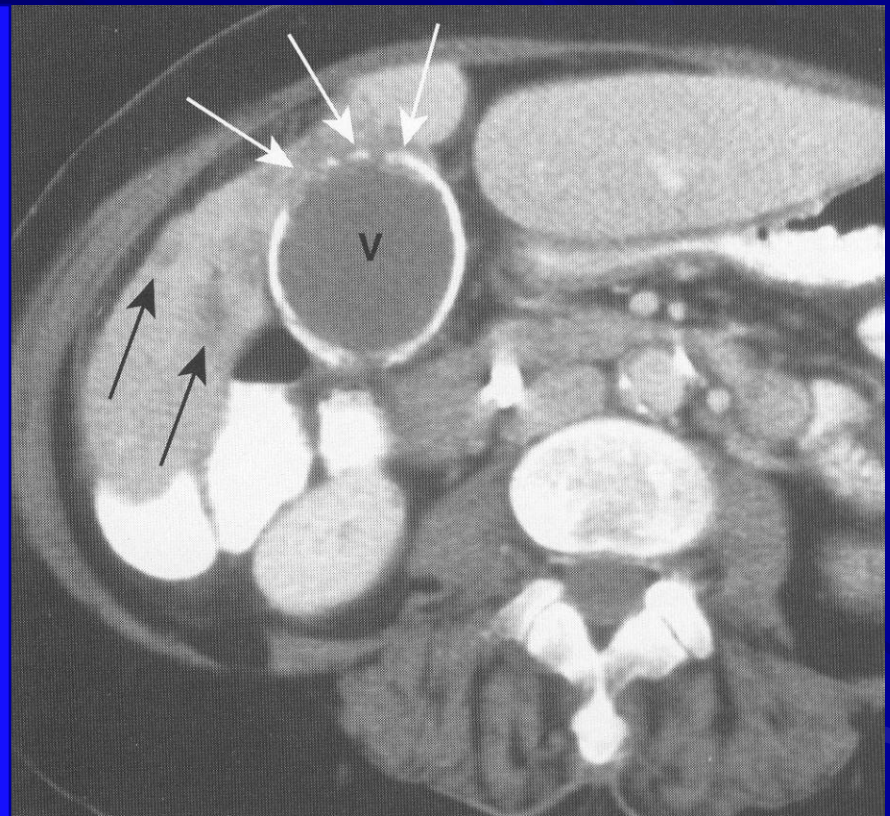
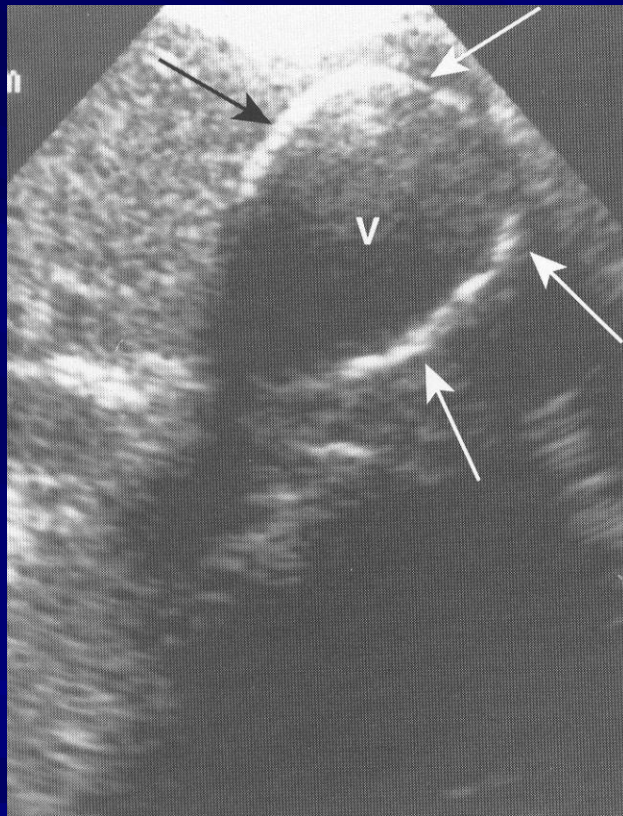




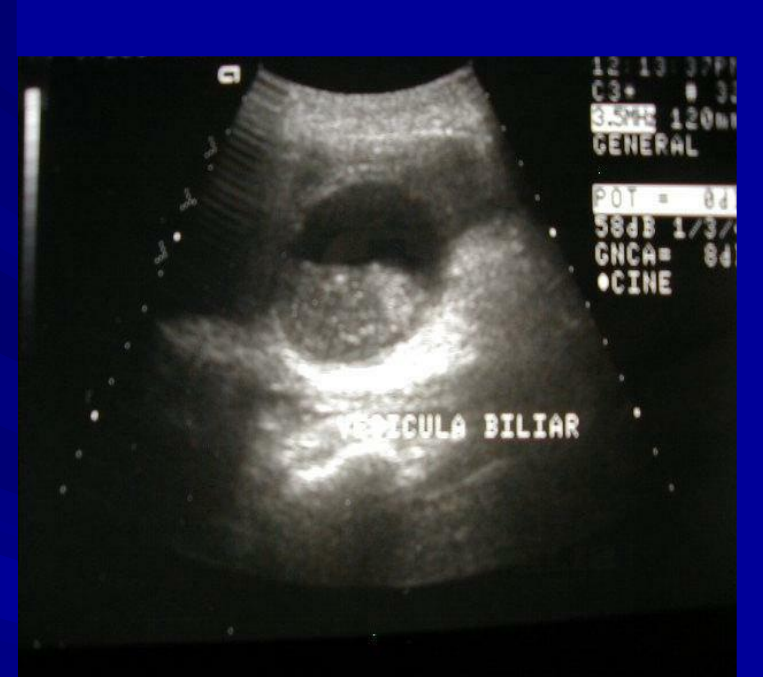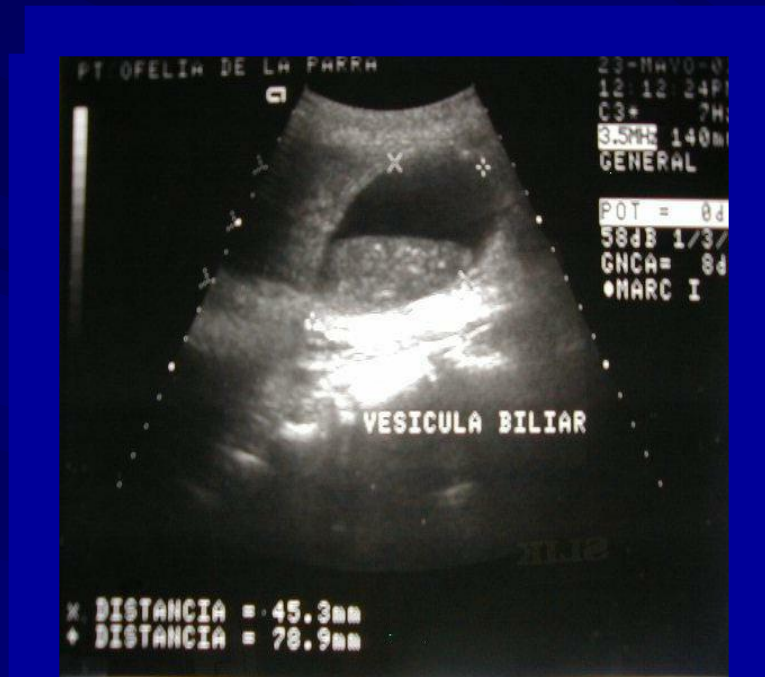# **VESICULA EN PORCELANA**

- CALCIFICACION DE LA PARED**
- COLELITIASIS 95%**
- MAS FRECUENTE EN MUJERES**
- ASOCIADO A CARCINOMA**
- NO HAY DOLOR AGUDO**
- MOLESTIAS CRONICAS EN HIPOCONDRIO**
- DISPEPSIA**
- FLATULENCIA**
- INTOLERANCIA A GRASAS**

# VESICULA EN PORCELANA



# LODO BILIAR



- **CONSTITUIDO POR MATERIAL GRANULAR Y RESTOS ECOGENICOS QUE SE ACUMULAN POR AYUNO PROLONGADO O POR OBSTRUCCION**

# CARCINOMA DE VESICULA

ENGROSAMIENTO DE LA PARED

PRESENCIA DE LITOS

DISPEPSIA

MOLESTIAS EN HIPOCONDRIO DERECHO

INTOLERANCIA A GRASAS

IRRITACION



INFLAMACION  
CRONICA



CANCER DE VESICULA

LITIASIS



# CARCINOMA DE VESICULA

